

## Original Article

Dan Med J 2023;70(1):A08220469

# Surgical treatment of symptomatic simple liver cysts

Kathrine Dalgas Hartmann &amp; Frank Viborg Mortensen

Department of Surgery, Section for Upper Gastrointestinal and Hepato-pancreato-biliary Surgery, Aarhus University Hospital, Denmark

Dan Med J 2023;70(1):A08220469

**ABSTRACT**

**INTRODUCTION.** Simple hepatic cyst (SHC) can cause symptoms due to compression of the surrounding structures. The aim of the present study was to evaluate symptoms, treatment, recurrence rate and post-operative complications of patients treated for symptomatic SHC.

**METHODS.** Patients were identified from medical records. The inclusion criteria were symptomatic SHC, treatment with percutaneous aspiration or laparoscopic deroofing or both. Age, gender, symptoms, type of treatment, post-operative complications, recurrence of symptomatic liver cyst and time of symptomatic relief were recorded.

**RESULTS.** A total of 66 patients were included. The most common symptom was abdominal discomfort and/or pain, which was reported in 88%. Nine patients received two, one received three and one received four cyst aspirations before further treatment or no recurrence of symptoms. A total of 84.7% had recurrence of symptoms after aspiration. Forty patients were treated with laparoscopic deroofing, 37 (92.5%) had relief of symptoms. Complications reported after cyst drainage was prolonged drainage (n = 1), dyspnoea (n = 1), bleeding (n = 2) and peritonitis (n = 2). After laparoscopic deroofing, the only post-operative complication was wound infection (n = 2).

**CONCLUSIONS.** The present study showed that percutaneous aspiration of symptomatic SHC should be performed to ensure that the symptoms are related to the cyst. Laparoscopic deroofing has proven a definitive treatment for simple SHC and is associated with a low recurrence rate and few post-operative complications.

**FUNDING.** none.

**TRIAL REGISTRATION.** not relevant.

Simple hepatic cyst (SHC) is one of the most common liver lesions with no malignant potential. Some 0.1-7% of the population are estimated to have SHC, which tends to affect women more often than men and patients older than 40 years [1-3]. For asymptomatic cysts, the female-to-male ratio is 2:1; for symptomatic cysts, 9:1. SHC can be diagnosed with abdominal ultrasound, CT or MRI. Typically, radiographic features include a round or ovoid shape of the cyst with well-defined margins. SHC is a benign lesion filled with serous fluid and lined with a thin, practically invisible wall consisting of cells identical to that of bile ducts [2, 3]. Very seldomly the cyst communicates with the biliary tree and is thought to be a congenital malformation originating from an aberrant bile duct, which has lost communication with the biliary tree [4, 5].

SHC is often an incidental finding and is commonly small and asymptomatic. The cyst, however, can grow to more than 20 cm and manifest with symptoms caused by its size and pressure on the surrounding structures.

Symptoms associated with the compression of the digestive tract may include abdominal pain, nausea, vomiting, bloating, early satiety and weight loss. Compression of the diaphragm may cause dyspnoea. Compression to the biliary system may cause icterus and fatigue. Hepatomegaly and larger cysts may be palpable in the abdomen during physical examination [3, 6-8]. Rarely, cysts present more serious complications such as bleeding, rupture, infection, inferior vena cava thrombosis, compression of the portal and liver veins, cholecystitis and deep vein thrombosis in the lower extremities [3, 7-9].

Asymptomatic liver cysts do not require treatment. Symptomatic liver cysts are primarily treated with percutaneous aspiration. Ultrasound-guided needles or catheters are inserted into the cyst for drainage of cyst fluid. Percutaneous aspiration of cyst fluid is relatively non-invasive and will determine whether the cyst is the source of a patient's symptoms if symptomatic relief is achieved. Due to high recurrence rates after cyst aspiration (78-100%), further treatment with other methods is usually needed. Procedures seen as more definitive include laparoscopic or open deroofing, hepatic resection and percutaneous aspiration followed by injection of a sclerosing agent (PAS) [1, 10, 11].

Laparoscopic deroofing on symptomatic SHC was first described in 1991 and has since shown good long-term results [1, 11, 12]. Laparoscopic deroofing is a procedure that combines aspiration of cyst fluid with excision of the extra-hepatic cyst wall [13]. It is often considered the preferred treatment with recurrence rates falling in the 0-20% range and morbidity being observed in 0-25% of the patients [1, 11]. Post-operative complications include wound infection, bile leak, chest infection, prolonged post-procedure drainage, air embolism, pleural effusion, dyspnoea and bleeding [1, 3].

The overall study objective was to evaluate the symptoms, treatment, recurrence rate and post-operative complications of patients hospitalised with symptomatic simple liver cysts over the past ten years at our university clinic.

## METHODS

In this study, a total of 66 consecutive patients from Aarhus University Hospital were included. The study was approved by the local Board of Directors at Aarhus University Hospital as a research project. Using the diagnostic code DK768E (Liver cyst) from the WHO, we extracted a list of the past ten years of hospitalisations from the hospital records (2013-2022). The inclusion criteria were to have symptomatic simple liver cyst and receive treatment with percutaneous aspiration, laparoscopic deroofing or both.

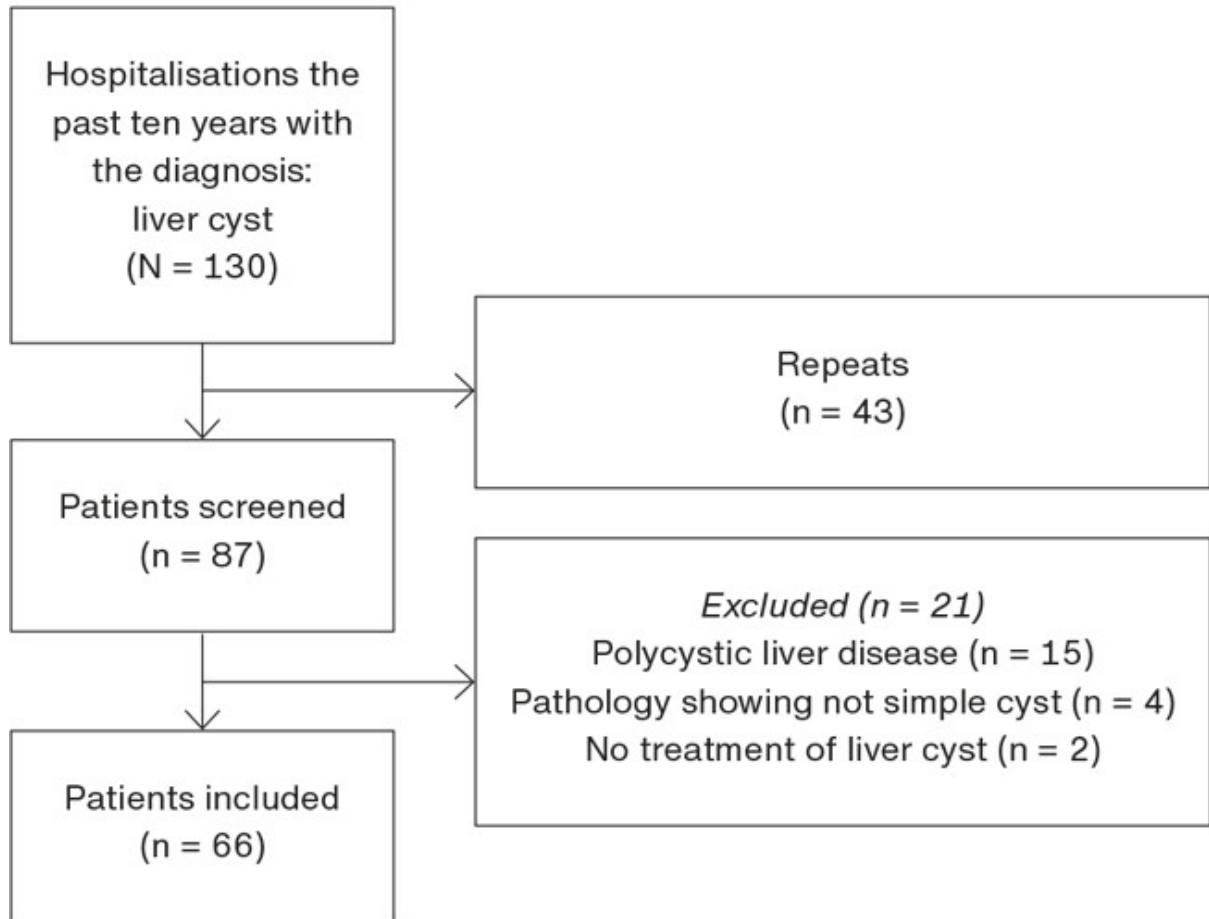
From patient records, age, gender, symptoms, type of treatment, post-operative complications, recurrence of symptomatic liver cyst and time of symptomatic relief were noted. Using information from patient records on patients treated with multiple liver cyst aspirations, we registered each time they had a new procedure done.

*Trial registration:* not relevant.

## RESULTS

In the course of the ten-year period, 130 hospitalisations for symptomatic SHC were documented of which 43 were repetitions. A total of 87 patient records were systematically screened. Hereof, 21 were not eligible for this study and were excluded (**Figure 1**). A total of 66 patients were included, of whom nine received two, one received three and one received four cyst aspirations before further treatment or no recurrence of the symptomatic cyst occurred. Six patients were not treated with percutaneous aspiration and had laparoscopic deroofing as their primary treatment. This yields a total of 74 cyst aspirations.

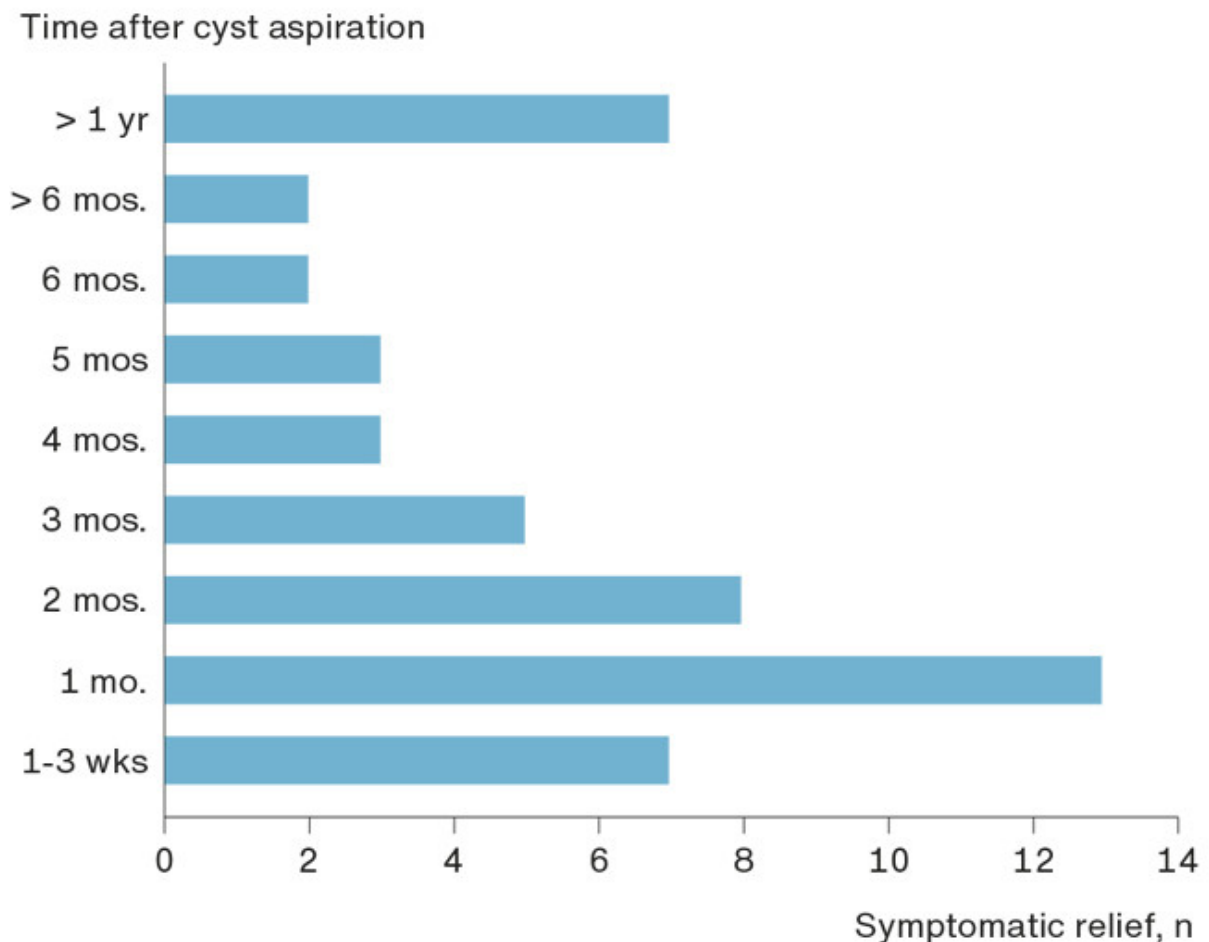
**FIGURE 1** Patient selection flow chart.



A total of 12 (18%) of the 66 patients had incidental findings of liver cysts in connection with examination for other diseases. These patients did not receive treatment until the cysts became symptomatic. An exception was made for one patient who needed the cyst drained before spinal surgery.

Data on symptomatic relief were available from 59 of the 74 cyst aspirations. Six patients had no symptomatic relief after cyst aspiration, six patients had their cyst further treated shortly after cyst aspiration before they developed symptoms again, and three of the patient records did not provide information on this topic. In all, 50 (84.7%) patients had recurrence of symptoms and nine (15.3%) had no recurrence. Two thirds of the patients experienced symptomatic relief between one week and three months with a mean symptomatic relief time of 6.5 months (range: one week – five years) (Figure 2).

**FIGURE 2** An overview presenting how long the patients had symptomatic relief after cyst aspiration before they experienced recurrence of symptoms and a new treatment was initiated.

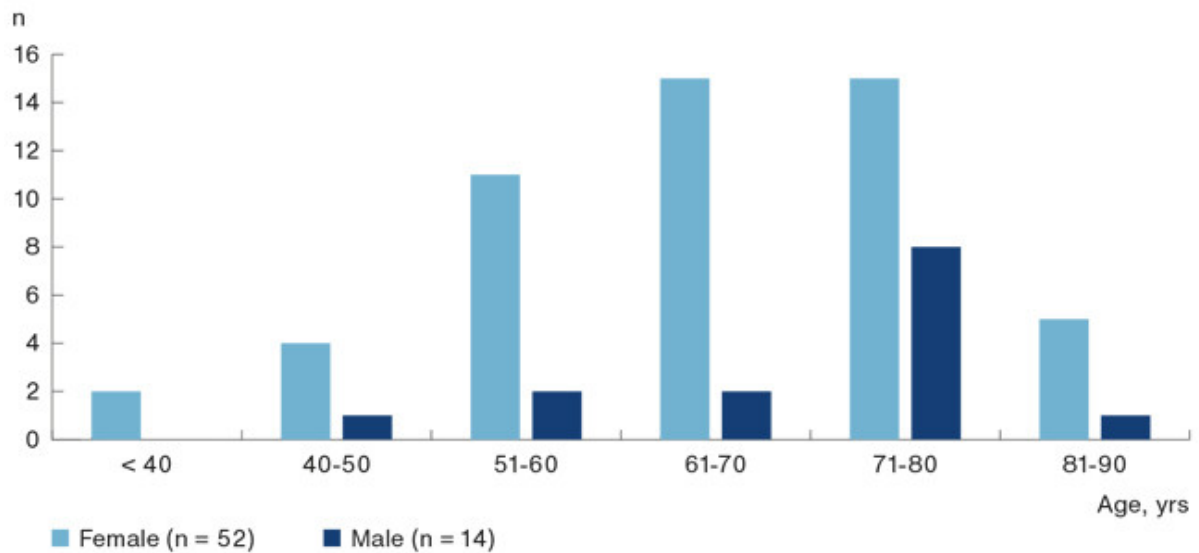


Forty patients received laparoscopic deroofing of the cyst. Ten patients did not undergo laparoscopic deroofing after cyst aspiration and recurrence of symptomatic cyst. Six patients received treatment with PAS, two had open deroofing and two had liver cyst resection. One patient did not receive further treatment of the cyst despite recurrence of symptoms. Among the 40 patients who received treatment with laparoscopic deroofing, 37 (92.5%) had no recurrence of symptomatic cyst; only three (7.5%) patients had recurrence.

The overall post-operative complication rate was low. Post-operative complications were described in four (5.4%) of the 74 cyst aspirations and two (5%) of the 40 patients treated with laparoscopic deroofing. The complications reported after cyst drainage were prolonged drainage (n = 1), dyspnoea (n = 1), bleeding (n = 2) and peritonitis (n = 2). After laparoscopic deroofing, the post-operative complication reported was wound infection (n = 2).

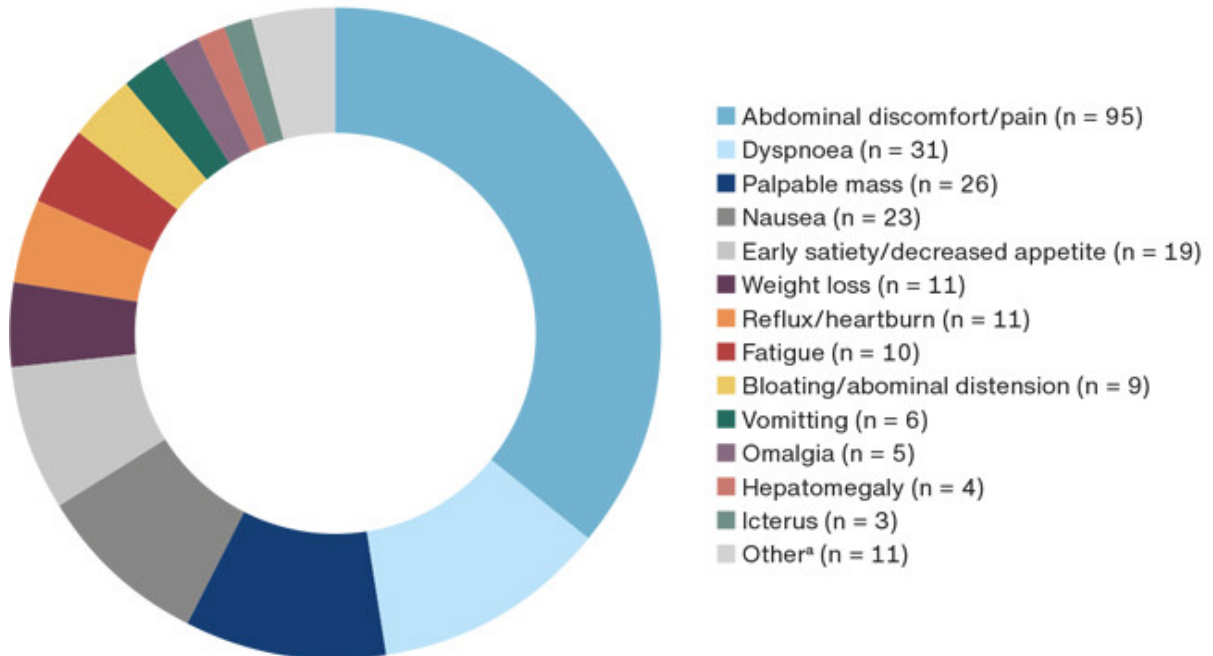
As shown in **Figure 3**, 52 (79%) of the patients were women. The majority of patients were between 51-80 years of age with a mean age of 62 years (range: 30-90 years).

**FIGURE 3** Age and sex distribution of patients treated for symptomatic liver cysts with percutaneous aspiration, laparoscopic deroofing or both.



Cyst aspiration and laparoscopic deroofing combined, a total of 114 procedures were conducted. Information on symptoms from the six patients with no symptomatic relief after percutaneous aspiration was not registered as the symptoms were unrelated to the patients' liver cyst. Information on symptoms was registered for 108 procedures. Two thirds of the patients reported more than one symptom before treatment. A total of 31 patients only reported one symptom before treatment of whom 93.5% (n = 29) had abdominal discomfort and/or pain. **Figure 4** presents data on the most common symptoms from SHC described by the patients in this study.

**FIGURE 4** Most common symptoms from simple liver cysts.



a) Including rupture (n = 1), infection (n = 1), bleeding (n = 2), cholecystitis (n = 1), compression of portal and liver veins (n = 2), inferior vena cava thrombosis (n = 1), deep vein thrombosis (n = 1) and diarrhoea (n = 2).

## DISCUSSION

In the ten-year study period, 66 patients were treated for symptomatic SHC with either percutaneous aspiration, laparoscopic deroofing or both at Aarhus University Hospital, Denmark. The most common symptom reported was abdominal discomfort and/or pain (88% of the patients). This result correlates with other studies that found abdominal pain to be the most frequently observed symptom, which was seen in 60-92% of patients with SHC [6, 14-17].

In all, 74 percutaneous cyst aspirations and 40 procedures with laparoscopic deroofing were performed. After cyst aspiration, 84.7% of the patients had recurrence of symptomatic SHC. Percutaneous aspiration gives patients quick symptomatic relief, but the effect is typically temporary. Recurrence of symptomatic SHC after percutaneous aspiration is high, but the procedure is minimally invasive, has a low complication rate and is used for diagnostic workup before laparoscopic surgery [15, 17-19].

After laparoscopic deroofing, 7.5% of the patients had recurrence of their symptomatic cyst. In a review of 85 cases, five patients (5.8%) had symptomatic recurrences [4]. In another systematic review of 348 patients who underwent laparoscopic treatment, 2.1% had persisting symptoms after treatment and 5.6% had recurrence of the symptomatic cyst [6]. The results in other studies vary widely with symptomatic recurrence rates falling in the 8-23% range [14-17, 19]. Factors such as inadequate deroofing, previous operation in the abdomen with formation of adhesions, deep-seated cysts, and cysts in the posterior segments of the liver may impact recurrence of symptomatic cysts [15]. The use of electrocoagulation and argon beam coagulation on the epithelium in the remaining cystic cavity may reduce recurrence rates as may also fixation of an omentum transposition flap to prevent early closure of the cyst [5, 15].

Laparoscopic deroofing of SHC is often referred to as standard treatment. A recent systematic review compared open deroofing, laparoscopic deroofing, and PAS, favouring laparoscopic deroofing and PAS with the best outcomes. Recurrence of symptomatic SHC and cyst size correlated. A larger mean cyst size in patients treated with laparoscopic deroofing (12.7 cm) than in those treated with PAS (9.3 cm) may have negatively influenced the results of treatment and recurrence of symptoms. Furthermore, a higher rate of patients underwent treatment prior to surgical treatment (9.9%) compared to PAS (0.3%) and the mean age was higher for patients treated with laparoscopic deroofing (62 years) than for patients receiving PAS (58 years) [6].

In this study, only two patients (5%) treated with laparoscopic deroofing had wound infection as a post-operative complication. Gigot et al. [15] reported minor post-operative complications such as cardiac arrhythmia, severe shoulder pain, acute dyspnoea and pleural effusion in 15% of patients. In their meta-analysis, Furumaya et al. [6] reported post-operative complications in 1.7% of patients compared with complications in 25% of patients reported in a retrospective study by Martin et al. [16]. Furumaya et al. [6] included 18 studies on laparoscopic deroofing in their meta-analysis and only major complications were registered. Conversely, Martin et al. [16] registered all complications. Possible minor post-operative complications which may influence the findings by Martin et al. [16] could be unaccounted for in the meta-analysis by Furumaya et al. [6]. Post-operative complication rates vary widely, but – to our knowledge – no post-operative mortality after laparoscopic deroofing has been reported in the literature.

A strength of this study is that data were collected from a consecutive number of patient records at a single institution. A small number of health professionals performed the procedures, which means that no significant difference occurred in the procedures of percutaneous aspiration and laparoscopic deroofing. Retrospective studies are not prone to loss to follow-up, but some key information cannot be collected from patient records. Specific data were not collected at the time of hospitalisation as the data were originally collected for other purposes. Furthermore, retrospective studies are prone to several biases as we only see the association but cannot determine causality.

## CONCLUSIONS

In conclusion, the present study showed that percutaneous aspiration of symptomatic simple liver cysts should be performed to ensure that symptoms are, in fact, related to the cyst. Laparoscopic deroofing has proven a definitive treatment for simple symptomatic liver cysts and is associated with a low recurrence rate and few post-operative complications.

**Correspondence** *Kathrine Dalgas Hartmann*. E-mail: hartmann.arbejde@gmail.com.

**Accepted** 29 November 2022

**Conflicts of interest** none. Disclosure forms provided by the authors are available with the article at [ugeskriftet.dk/dmj](https://ugeskriftet.dk/dmj)

**References** can be found with the article at [ugeskriftet.dk/dmj](https://ugeskriftet.dk/dmj)

**Cite this as** Dan Med J 2023;70(1):A08220469

## REFERENCES

1. Blonski WC, Campbell MS, Faust T, et al. Successful aspiration and ethanol sclerosis of a large, symptomatic, simple liver cyst: case presentation and review of the literature. *World J Gastroenterol*. 2006;12(18):2949-54.
2. Weerakkody Y, Jones J. Simple hepatic cyst. <https://radiopaedia.org/articles/17852> (26 Jul 2022).

3. Ramia JM, de La Plaza R, Figueras J, Garcia-Parrano J. Benign non-parasitic hepatic cystic tumours. *Cir Esp*. 2011;89(9):565-73.
4. Moorthy K, Mihssin N, Houghton PW. The management of simple hepatic cysts: sclerotherapy or laparoscopic fenestration. *Ann R Coll Surg Engl*. 2001;83(6):409-14.
5. Klingler PJ, Gadenstätter M, Schmid T et al. Treatment of hepatic cysts in the era of laparoscopic surgery. *Br J Surg*. 1997;84(4):438-44.
6. Furumaya A, van Rosmalen BV, de Graeff JJ et al. Systematic review on percutaneous aspiration and sclerotherapy versus surgery in symptomatic simple hepatic cysts. *HPB (Oxford)*. 2021;23(1):11-24.
7. Garcea G, Rajesh A, Dennison AR. Surgical management of cystic lesions in the liver. *ANZ J Surg*. 2013;83(7-8):E3-E20.
8. Tonolini M, Rigioli F, Bianco R. Symptomatic and complicated nonhereditary developmental liver cysts: cross-sectional imaging findings. *Emerg Radiol*. 2014;21(3):301-8.
9. Gall TM, Oniscu GC, Madhavan K et al. Surgical management and longterm follow-up of non-parasitic hepatic cysts. *HPB (Oxford)*. 2009;11(3):235-41.
10. Cleveland Clinic. Liver cysts. <https://my.clevelandclinic.org/health/diseases/17178-liver-cyst> (26 Jul 22).
11. Reid-Lombardo KM, Khan S, Sclabas G. Hepatic cysts and liver abscess. *Surg Clin North Am*. 2010;90(4):679-97.
12. Z'Graggen K, Metzger A, Klaiber C. Symptomatic simple cysts of the liver: treatment by laparo-scopic surgery. *Surg Endosc*. 1991;5(4):224-5.
13. Bernts LHP, Echternach SG, Kievit W et al. Clinical response after laparoscopic fenestration of symptomatic hepatic cysts: a systematic review and meta-analysis. *Surg Endosc*. 2019;33(3):691-704.
14. Maruyama Y, Okuda K, Ogata T et al. Perioperative challenges and surgical treatment of large simple, and infectious liver cyst - a 12-year experience. *PLoS One*. 2013;8(10):e76537.
15. Gigot JF, Legrand M, Hubens G et al. Laparoscopic treatment of nonparasitic liver cysts: adequate selection of patients and surgical technique. *World J Surg*. 1996;20(5):556-61.
16. Martin IJ, McKinley AJ, Currie EJ et al. Tailoring the management of nonparasitic liver cysts. *Ann Surg*. 1998;228(2):167-72.
17. Petri A, Höhn J, Makula E et al. Experience with different methods of treatment of nonparasitic liver cysts. *Langenbecks Arch Surg*. 2002;387(5-6):229-33.
18. Saini S, Mueller PR, Ferrucci JT et al. Percutaneous aspiration of hepatic cysts does not provide definitive therapy. *AJR Am J Roentgenol*. 1983;141(3):559-60.
19. Koperna T, Vogl S, Satzinger U, Schulz F. Nonparasitic cysts of the liver: results and options of surgical treatment. *World J Surg*. 1997;21(8):850-5.