

# Intra-corporeal anastomosis in laparoscopic surgery for benign colorectal disease

Jacob Antonsen, Rogini Balachandran, Finn Stigsen Holm & Ismail Gögenur

## ABSTRACT

**INTRODUCTION:** Recent studies have described the benefits of performing bowel resections for benign and malignant diseases as a total laparoscopic procedure with intra-corporeal anastomosis. We describe our preliminary experience with total laparoscopic surgery for benign lower gastrointestinal diseases.

**METHODS:** All patients (n = 32) who had received elective bowel surgery with intra-corporeal anastomosis for benign diseases between November 2013 and August 2015 were included in this retrospective study.

**RESULTS:** A total of 15 patients (47%) had a primary anastomosis, 17 patients (53%) had a stoma reversal. The median length of stay was five days (range: 3-16). Surgical complications requiring re-operation were present in five patients (Clavien-Dindo grade IIIb) of whom two presented with anastomotic leaks (6%; 95% confidence interval: 2-20%). No post-operative medical complications according to the Clavien-Dindo Classification were seen. The median duration of surgery was 127 minutes (range: 61-211 min.). No deaths occurred.

**CONCLUSION:** A total laparoscopic approach to benign lower gastrointestinal diseases with intra-corporeal anastomosis was feasible.

**FUNDING:** none.

**TRIAL REGISTRATION:** The trial is registered with the Danish Data Protection Agency.

Several studies have proven the benefits of laparoscopic bowel resection compared with open or hand-assisted surgery. Recent studies have highlighted the feasibility [1, 2] and the benefit [3] of performing a complete laparoscopic procedure with total intra-corporeal anastomosis (IA) compared with an extra-corporeal anastomosis (EA). A large study with 105 patients who underwent large bowel resection for benign and malignant disease showed an earlier recovery of bowel function, a lower need for analgesics and a shorter hospital stay in the IA group [4]. One of the reasons is believed to be the option to create a shorter and more optimal incision site for extraction of the specimen.

A primary challenge with the extracorporeal anastomosis is the need for externalisation of the bowel in order to perform the anastomosis; this procedure causes longer incisions and added tension to the mes-

entery and its arteries. The latter might entail an increased risk of portal vein thrombosis and mesenteric vascular occlusion [5, 6]. Especially in patients with a short mesentery, i.e. obese patients or patients with inflamed bowel and/or thickened mesentery, this can result in a need for conversion to open surgery.

Here we describe our preliminary experience with total laparoscopic resection and IA in patients undergoing elective benign large and small bowel surgery.

## METHODS

All patients who had an IA during elective surgery for a benign disease from November 2013 to August 2015 were included in the study. All malignancies and/or acute and emergency surgeries were excluded. Data were extracted from our electronic medical reports and the anaesthesia charts. All patients had a minimum follow-up of 30 days.

The decision to perform a primary anastomosis versus a stoma was made intra-operatively by the leading surgeon, depending on the amount of bowel inflammation, fistulation and whether or not peritonitis or pre-stenotic bowel dilatation was found. When we decided to perform an anastomosis, we always opted for IA rather than EA. We did not defer from performing an IA on indication of the patient's risk profile (comorbidities, etc.). In our patient group with stoma reversal where we were able to access the peritoneal cavity laparoscopically, we always opted for IA. Thus, our population is representative of the normal patient population receiving laparoscopic surgery for benign diseases.

All anastomoses were performed as side-to-side in an iso-peristaltic fashion, with either an Echelon Endopath linear stapler (Ethicon, USA) or the electronic iDrive stapler (Covidien), using a 60 mm linear cartridge for both (Figure 1A). The enterotomy was closed with a 15-cm continuous self-locking V-Loc (Covidien) suture in the transverse direction in two layers, or Vicryl 3-0 (Ethicon, USA) running suture in the longitudinal direction in two layers (Figure 1B). Specimen extraction was mainly done through a small muscle-sparing Pfannestiel incision (57%), alternatively through previous incisions (29%), an Endobag (7%) or a lower midline incision (7%). The surgeons did not record the length of the incision.

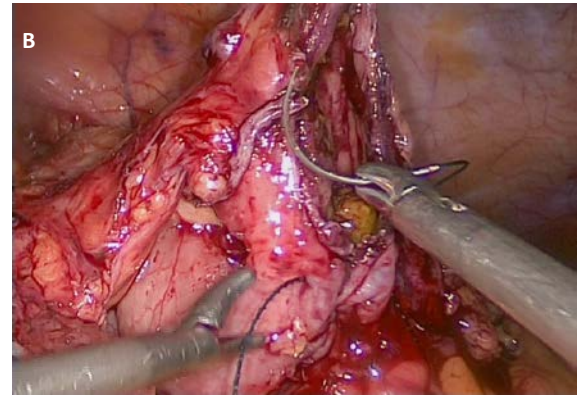
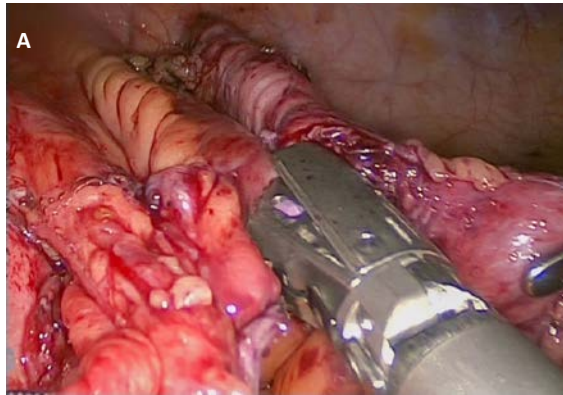
## ORIGINAL ARTICLE

Department of Surgery,  
Køge Hospital,  
Denmark

Dan Med J  
2017;64(10):A5413


 FIGURE 1

**A.** The intra-corporeal stapling of the anastomosis using a linear laparoscopic stapler. **B.** The intra-corporeal suturing of the enterotomy using the self-locking V-Loc (Covidien) suture.



All procedures were performed by one of two staff surgeons: one specialised in inflammatory bowel disease (IBD) surgery and minimally invasive surgery, and the other specialised in gastric bypass surgery with an experience of 250 Roux-en-Y gastric bypass procedures. A junior or senior resident was assigned as the staff surgeon's assistant.

The following data were recorded: age, sex, American Society of Anesthesiologists (ASA) score, body mass index, smoking, diabetes, hypertension, cardiovascular disease, chronic obstructive pulmonary disease, asthma, IBD or gastro-intestinal malignancy. We also recorded whether a primary anastomosis or a stoma reversal was performed. Further-more, the use of V-Loc or Vicryl was registered along with the type of anastomosis and the main surgeon on the case as well as operating time, length of hospital stay (LOS) and post-operative surgical and medical complications according to the Clavien-Dindo classification.

Data are presented as medians with interquartile range, range and percentages. Incidences are presented as number (% with 95% confidence interval (CI)). Data were analysed using SPSS (IBM, USA, Vers. 22). The data collection was approved by the Danish Data Protection Agency.

*Trial registration:* The trial is registered with the Danish Data Protection Agency.

## RESULTS

In all, 32 patients were included during the 21-month trial period. Patient demographics are presented in **Table 1**. The majority of our patients, 22 (69%), suffered from IBD.

A total of 15 (47%) of our patients were on either low-dose systemic steroid (< 20 mg a day) or immuno-

modulation (adalimumab (Humira) or infliximab (Remicade) < 30 days before the surgery).

Surgical characteristics are presented in **Table 2**. A total of 17 patients (53%) had stoma reversal. Among them, seven had undergone a previous laparoscopic bowel resection and ten had undergone a previous open bowel resection. All stomas in our population were fashioned as an end-stoma with the efferent bowel remaining as a blind loop intra-abdominally. The remaining 15 patients (47%) (out of 32 patients) had a resection with primary anastomosis. More than two thirds, 22 patients (69%), were ileo-ascending anastomoses. Ileo-jejunal anastomoses and ileo-transverse anastomoses made up the remainder of the procedures, equaling a total of five patients (16%). A V-loc was used in the majority of the anastomoses (27 patients, 84%). Post-operative data are shown in **Table 3**.

Our median LOS was five days (range: 3-16 days), with a single patient staying 16 days due to early recognised anastomotic leakage and peritonitis necessitating further surgery.

Five patients (16%; 95% CI: 7%-32%) underwent re-laparoscopy on suspicion of anastomotic leak. Two patients (6%; 95% CI: 2%-20%) had a small anastomotic leak and one patient had 500 ml blood in the abdomen from a port-site bleeding. The two remaining patients had normal findings at re-laparoscopy.

None of the three patients (9%; 95% CI: 3%-24%) with no evidence of anastomotic leakage on re-laparoscopy received any further surgical interventions, but were treated with intra-venous antibiotics and discharged few days after their second operation. With respect to complications, besides the five Grade IIIb complications mentioned above, we saw no further complications that deviated from the normal post-operative course. There were no deaths within 30 days after surgery.

## DISCUSSION

In this study, we observed that use of IA for benign lower gastrointestinal surgery is feasible and safe. However, the current literature on this subject is sparse, and further studies with larger sets of patients are required to fully highlight this issue.

Several articles have discussed the benefits of a total laparoscopic approach to bowel resection [1-5, 7-9]. Most current literature deals with colonic resection in cancer surgery, and especially with right-sided hemicolectomies, or Roux-en-Y gastric bypass surgery.

Regarding anastomotic leakages, previous reports have shown similar rates of leakage between IA and EA in both benign and malignant colorectal surgery [7, 10]. A review from 2013 of 13 studies comprising a total of 611 cases described a leakage rate of 1% (range: 0-8.5%) and a rate of re-operations of 0.8% (range: 0-25%) [8]. In our study, we found five patients (16%; 95% CI: 7%-32%) with post-operative surgical complications, all within eight days of their primary operation (range: 3-8 days). Not all of our patients had a significant rise in C-reactive protein on the day of their re-operation (range: 28-275), but were re-operated on clinical and radiological suspicion of surgical complications. The high percentage of post-operative complications in our population may be due to the small number of patients and can therefore not be subjected for in statistical analysis. A larger group size is necessary to produce valid data on the percentage of postoperative surgical complications in this population.

When looking at surgery for colorectal cancer, comparing midline incision to laparoscopic procedures with non-midline extraction sites, we observed a reduction in the risk of incisional hernias from 12.9% to 2.4% [11]. A Cochrane review described a non-significant difference of 7.9% versus 10.9% in laparoscopic assisted versus open surgery [12]. As the incidence of port site hernias in total laparoscopic procedures is as low as 0.5%, possibly even lower when suturing the fascia of port sites > 10 mm [13], it seems plausible that there would be a benefit in performing total IA rather than EA.

The benefits of an IA described in colorectal surgery are sure to be the same in small bowel surgery, and the risk of stenosis is theoretically small with transversal suturing of the enterotomy [14].

One claim against IA in the earlier years was the increased operating room (OR) time, which was attributed mainly to the difficulty of laparoscopic suturing. However, it remains to be shown if the actual duration of surgery is longer when technical advances, i.e. self-holding sutures, electronic staplers, etc., are taken into account. Furthermore, performing an IA with less tension, less dissection and smaller incisions may also influence the OR time positively; in fact, a retrospective study of

 TABLE 1

Baseline patient characteristics.

Age, yrs, median (range)	42 (20-73)
Male sex, n (%)	10 (31)
ASA score, median (range)	2 (1-3)
BMI, kg/m <sup>2</sup> , median (range)	25 (16-40)
Inflammatory bowel disease, n (%)	22 (69)
Diabetes, n (%)	2 (6)
Hypertension, n (%)	6 (19)
CVD, n (%)	2 (6)
COPD/asthma, n (%)	3 (9)
Pre OP systemic steroid, n (%)	3 (9)
Pre OP immunomodulation, n (%)	12 (38)
Smoker, n (%)	8 (25)

ASA = American Society of Anesthesiologists; BMI = body mass index; COPD = chronic obstructive pulmonary disease; CVD = cardiovascular disease; Pre OP = preoperative.

 TABLE 2

Surgical characteristics.

Primary anastomosis, n (%)	15 (47)
Stoma reversal, n (%)	17 (53)
V-Loc, n (%)	27 (84)
Ileo-ileo anastomosis, n (%)	5 (16)
Ileo-transversal anastomosis, n (%)	5 (16)
Ileo-ascending anastomosis, n (%)	22 (69)
OR time, min., median (range)	127 (61-211)

OR = operation.

 TABLE 3

Postsurgical characteristics.

Length of stay, days, median (range)	5 (3-16)
Post-operative medical complications, n	0
<i>Post-operative surgical complications, n (%; 95% CI)</i>	
Negative re-laparoscopy	3 (9; 3-24)
Anastomotic leak	2 (6; 2-20)
Total	5 (16; 7-32)

CI = confidence interval.

100 patients found a shorter mean OR time in the total laparoscopic group than in laparoscopic assisted right hemicolectomies [9]. One clear advantage of IA over EA is that the surgeon does not have to externalise the bowel to perform the anastomosis. Especially in obese patients or other patients with a shortened mesentery this could create an increased risk for conversion to open surgery. We had no conversions in our dataset.

## CONCLUSION

Our data show that a total laparoscopic approach with IA is a feasible technique in entero-entero anastomoses in benign diseases.

**CORRESPONDENCE:** *Jacob Antonsen*. E-mail: jacobantonsen@dadlnet.dk

**ACCEPTED:** 15 August 2017

**CONFLICTS OF INTEREST:** Disclosure forms provided by the authors are available with the full text of this article at [www.danmedj.dk](http://www.danmedj.dk)

## LITERATURE

1. Hellan M, Anderson C, Pigazzi A. Extracorporeal versus intracorporeal anastomosis for laparoscopic right hemicolectomy. *JLS* 2009;13:312-7.
2. Lee KH, Ho J, Akmal Y et al. Short- and long-term outcomes of intracorporeal versus extracorporeal ileocolic anastomosis in laparoscopic right hemicolectomy for colon cancer. *Surg Endosc* 2013;27:1986-90.
3. Lang RA, Huttel TP, Winter H et al. How safe are laparoscopic intracorporeal anastomoses? *Zentralbl Chir* 2005;130:65-70.
4. Grams J, Tong W, Greenstein AJ et al. Comparison of intracorporeal versus extracorporeal anastomosis in laparoscopic-assisted hemicolectomy. *Surg Endosc* 2010;24:1886-91.
5. Chaves JA, Idoate CP, Fons JB et al. A case-control study of extracorporeal versus intracorporeal anastomosis in patients subjected to right laparoscopic hemicolectomy. *Cir Esp* 2011;89:24-30.
6. Baixauli J, Delaney CP, Senagore AJ et al. Portal vein thrombosis after laparoscopic sigmoid colectomy for diverticulitis: report of a case. *Dis Colon Rectum* 2003;46:550-3.
7. Blumberg D. Laparoscopic colectomy performed using a completely intracorporeal technique is associated with similar outcome in obese and thin patients. *Surg Laparosc Endosc Percutan Tech* 2009;19:57-61.
8. Tarta C, Bishawi M, Bergamaschi R. Intracorporeal ileocolic anastomosis: a review. *Tech Coloproctol* 2013;17:479-85.
9. Fabozzi M, Allieti R, Brachet Contul R et al. Comparison of short- and medium-term results between laparoscopically assisted and totally laparoscopic right hemicolectomy: a case-control study. *Surg Endosc* 2010;24:2085-91.
10. Bergamaschi R, Haughn C, Reed JF et al. Laparoscopic intracorporeal ileocolic resection for Crohn's disease: is it safe? *Dis Colon Rectum* 2009;52:651-6.
11. Duepre HJ, Senagore AJ, Delaney CP et al. Does means of access affect the incidence of small bowel obstruction and ventral hernia after bowel resection? *Laparoscopy versus laparotomy*. *J Am Coll Surg* 2003;197:177-81.
12. Kuhry E, Schwenk WF, Gaupset R et al. Long-term results of laparoscopic colorectal cancer resection. *Cochrane Database Syst Rev* 2008;2: CD003432.
13. Swank HA, Mulder IM, la Chapelle CF et al. Systematic review of trocar-site hernia. *Br J Surg* 2012;99:315-23.
14. Mueller CL, Jackson TD, Swanson T et al. Linear-stapled gastrojejunostomy with transverse hand-sewn enterotomy closure significantly reduces strictures for laparoscopic Roux-en-Y gastric bypass. *Obes Surg* 2013;23: 1302-8.