

Takotsubo cardiomyopathy

An important differential diagnosis to acute myocardial infarction

Lene Hüche Nielsen,¹ MD, Kim Munk,² MD, Ole Goetzsche,³ DMSc, Evald Høj Christiansen,² PhD, and Bjarne Linde Nørgaard,¹ PhD

1) Department of Cardiology, Vejle Hospital. 2) Department of Cardiology, Aarhus University Hospital, Skejby. 3) Department of Cardiology, Aarhus University Hospital, Tage-Hansens Gade.

Correspondence: Lene Hüche Nielsen, Department of Cardiology, Vejle Hospital, DK-7100 Vejle, Denmark.

E-mail: lehuni@VGS.Vejleamt.dk

Dan Med Bull 2009;56:165-8

ABSTRACT

Introduction: Sparse information with regard to the electrocardiographic (ECG) changes in Takotsubo cardiomyopathy (TC) is available. The purpose of this study was to describe the clinical characteristics and electrocardiographic changes in a Danish cohort of patients with TC. We discuss the potential pathophysiological mechanisms of TC.

Methods: Cases were registered during a three year period. Patients who were hospitalized at Skejby Hospital suspected of acute myocardial infarction in whom coronary angiography was performed in the acute or subacute phase were registered. Data were obtained retrospectively from medical records and the hospitals laboratory database.

Results: Seven patients with TC were identified comprising six females and one male (mean age 70, range 53-81 years). In the acute phase all patients had ECG changes compatible with ST-elevation acute myocardial infarction (STEMI), as well as profound impaired left ventricular function with apical ballooning. At follow-up (range 1-82 weeks), both ECG and left ventricular function were normalized in all patients.

Conclusion: In the acute phase symptoms and ECG changes resemble those in patients with STEMI, hence acute coronary angiography is indicated in most cases. Pathophysiological aspects are discussed.

Takotsubo cardiomyopathy (TC) is a recently described cardiac syndrome with clinical and paraclinical manifestations mimicking ST-segment elevation myocardial infarction (STEMI) [1-8]. Patients with TC are characterized by: 1) symptoms, electrocardiographic changes and elevated cardiac biomarkers mimicking STEMI, 2) reversible wall-motion abnormalities involving apical and mid-portions of the left ventricle (LV), 3) absence of significant obstructive coronary disease or other conditions which may lead to LV systolic dysfunction (e.g., intracranial or sub-arachnoid haemorrhage, myocarditis, cocaine, hypertrophic cardiomyopathy etc.) and 4) a favourable prognosis [3, 4, 7].

Takotsubo cardiomyopathy is today categorized as a primary cardiomyopathy [9]. The syndrome is predominately observed in postmenopausal women, and is typically triggered by preceding emotional or physical stress. The syndrome was first described in Japan and named takotsubo-like LV dysfunction in reference to the associated end-systolic left ventricular morphology resembling a fishing pot (tako tsubo) with a narrow neck and a round bottom used for trapping octopuses in Japan [1] (Figure 1). Patients suffering from TC may in the acute phase have electrocardiographic changes very similar to those in the event of STEMI, whereas the changes later on are only sparsely described [10-12]. With focus on the electrocardiographic characteristics we will present our first experience with TC, and discuss possible pathophysiological mechanisms.

METHODS

From October 2002 to November 2005, patients with a suspected

acute myocardial infarction who underwent an acute or subacute coronary angiography at the Department of Cardiology, Aarhus University Hospital, Skejby, and met the following criteria: 1) ballooning of the LV-apex diagnosed by echocardiography or left ventriculography and 2) absence of obstructive coronary disease (no luminal stenosis $\geq 50\%$) were retrospectively enrolled in this study.

Three patients were directly hospitalized at Skejby Hospital, while four patients were transferred from local hospitals. Cases were reviewed and included in this study if the cardiologists (EHC, BLN) came to agreement about the diagnosis. Information about the clinical presentation, electrocardiographic and echocardiographic features in the acute phase and at follow-up were obtained from medical records and the laboratory database (LAPKA). Blood samples for measurement of troponin T (tnT) and creatine kinase myocardial band (CK-MB) were drawn on admission, after 6-9 hours and after 12-24 hours (Elexis 1010, Roche, respectively).

Electrocardiograms (ECG) on admission, during the hospital stay and at follow-up were analyzed for the presence of Q waves (≥ 1 mm in at least two contiguous leads in aVL, aVF, I, II, V5-6 or Q wave > 30 ms in V1-4), ST-segment elevation (at the J-point ≥ 2 mm in V1-3 or ≥ 1 mm in aVL, aVF, I, II, III, and V4-6 in at least two contiguous leads), ST-segment depression (≥ 1 mm in at least two contiguous leads measured 60 ms after the J-point), T-wave inversion (negative T-wave in I, II or V2-6), and the duration of the heart rate-corrected QT interval (QTc) was calculated by use of Bazett's formula ($QTc = QT/\text{square root of the RR interval}$, where $QTc > 440$ ms is prolonged). Echocardiography, coronary angiography and left ventriculography were performed according to daily practice. The coronary angiography was analyzed by experienced cardiologists (EHC, BLN).

RESULTS

Overall, 2824 acute coronary angiographies were performed during the study period. Eleven patients (0.4%) met the inclusion criteria. One patient (female, 78 years) was excluded as the review of the coronary angiography revealed significant coronary artery disease. One patient (female, 44 years) was excluded due to the presence of a dissection distally in the left coronary artery (LAD). Further two patients (female, 83 years, male, 81 years) were excluded due to lack of follow-up. This report therefore comprises seven patients (0.2%) with TC.

CLINICAL CHARACTERISTICS

The clinical characteristics of the patients are presented in Table 1. The study population comprises six females and one male (mean age of 70, range 53-81 years). All females were in the postmenopausal age. Five patients had emotional or physical stress associated

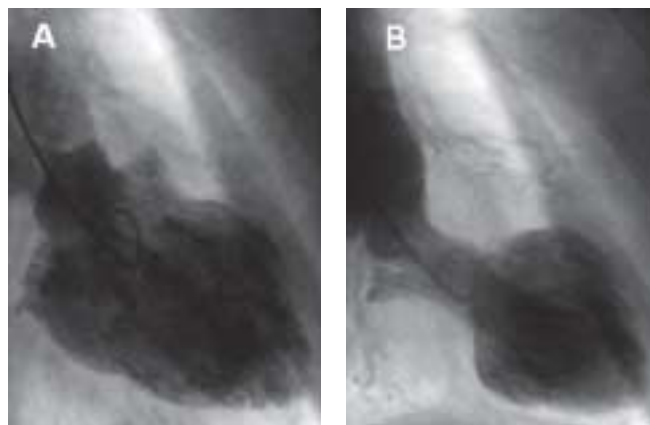

Figure 1. Ventriculography in A: diastole and B: end-systole. Akinesia of the midventricular or apical left ventricular segments and hyperkinesis of basal segments leading to an end-systolic left ventricular "takotsubo" configuration.

with onset of symptoms. Six patients had chest pain and/or dyspnoea. One patient presented with syncope without other cardiac symptoms.

COMPLICATIONS

During hospitalization five patients had clinical signs of heart failure, of which two patients were in cardiogenic shock requiring inotropic therapy (patient 3: dopamine, patient 7: dobutamine). Three patients had transient episodes of non-sustained ventricular tachycardia. Two patients had or developed pneumonia, which was treated by antibiotics.

ELECTROCARDIOGRAPHIC FEATURES

Electrocardiographic data are presented in Table 2. Figure 2 shows ECGs from two patients on admission, during hospitalization and at follow-up. ST-segment elevation in the admission ECG was documented in five of seven patients whereas Q-waves were present in

two. T-wave inversion was present on the admission ECG or on subsequent ECGs in all patients. The QTc interval was prolonged in all patients during the hospital stay. One patient received treatment with a potentially QTc-prolonging drug (cipramil 20 mg/day, patient 1) before admission. Follow-up ECG normalized in six patients except from the presence of discrete T-wave inversion in two patients. Only one patient had sustained Q-waves in the ECG (follow-up at one week). The QTc interval normalized in patients with >2 weeks of follow-up.

CARDIAC CATHETERIZATION

Four patients with a suspected acute myocardial infarction had coronary angiography performed ≤12 hours after symptom onset. The remaining three patients underwent coronary angiography within 24 hours, three and 11 days after the onset, respectively. No obstructive coronary disease was identified in any of the patients. The delay in the first case was due to an attempt of haemodynamic stabilizing

Table 1. Clinical and paraclinical characteristics.

Patient no.	Age (years) & sex	Arrhythmia	Trigger event	Symptoms	Troponin T ^a	CK-MB ^a	Ventriculography EF (%)	EF (%) / intra-ventricular gradient on admission	Weeks after admission / EF (%)
1	76 F		None	Dyspnoea	1.1	27	NP	40/none	6/>60
2	75 F		Death in family	Chest pain	0.5	27	NP	45/none	3/>60
3	70 F	NSVT	Hip fracture	Syncope	0.7	14	30	30/none	5/>60
4	53 F	Paroxysmic AFLI	None	Chest pain, dyspnea	0.5	11	45	40/33 mmHg	8/65
5	60 F		Knee operation	Chest pain, dyspnea	0.7	14	20	30/none	40/60
6	81 F		Pneumonia	Chest pain	2.6	46	35	35/none	6/65
7	57 M	Chronical AFLI	Seizure, shoulder luxation	Dyspnoea, cardiogenic shock	0.8	22	NP	15/none	2/60

a) Ref. values: troponin T < 0.1 µg/l; CK-MB < 10 µg/l.

AFLI = atrial fibrillation. CK-MB = creatine kinase myocardial band. EF = ejection fraction. F = female. M = male. NP = not performed. NSVT = episodes of non sustained ventricular tachycardia. QTc = heart rate-corrected QT interval.

Table 2. Electrocardiographic characteristics.

	Patient no.						
	1	2	3	4	5	6	7
<i>ECG on admission</i>							
Q-wave.....	No	No	No	No	V4-V5	V4-V6	No
ST-elevation.....	V2-V4	V2-V6, I, aVL	No	V2-V4	V2-V6	V2-V6, I, aVL	No
T-wave inversion.....	No	No	V3-V6, I, II, III, aVF	V4-V5	No	V2-V6, I, aVL	No
QTc (ms).....	415	468	780	380	440	470	400
<i>ECG during hospitalization</i>							
Day.....	3	3	2	2	2	2	4
Q-wave.....	No	No	No	No	No	V4-V6	No
ST-elevation.....	No	No	No	No	V2-V3	V2-V6, I, aVL	No
T-wave inversion.....	V2-V6, I, II, aVF	V2-V6, I, II, aVL, aVF	V2-V6, I, II, aVL, aVF	V3-V6, I, II, aVF	V3-V6	V2-V6, I, aVL	V2-V6
QTc (ms).....	730	467	703	570	460	519	490
<i>Follow-up ECG</i>							
Weeks.....	19	10	13	49	82	1	2
Q-wave.....	No	No	No	No	No	V3-V6	No
ST-elevation.....	No	No	No	No	No	V2-V4	No
T-wave inversion.....	No	Discrete V3-V6	No	No	No	Discrete V2-V6, I, II, aVL	No
QTc (ms).....	440	380	400	370	380	428	460

QTc = heart rate-corrected QT interval.

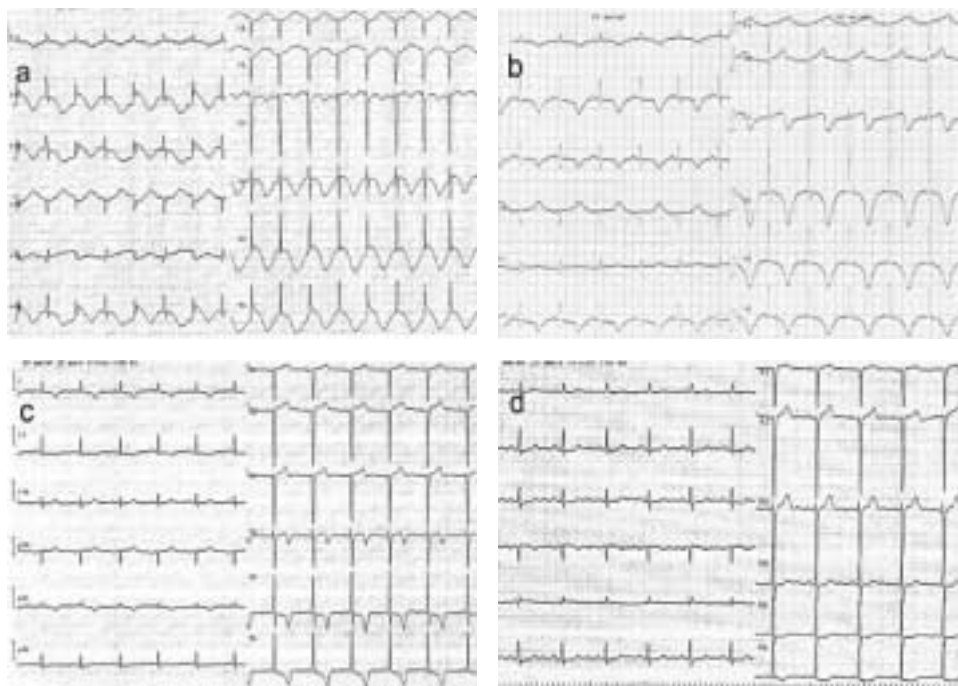


Figure 2. ECG from patient no. 3 on admission (a), day 2 (b), day 6 (c) and at follow-up 13 weeks after admission (d).

the patient with inotropic agents at the local hospital. In the second case the patient was initially hospitalized for surgery because of a fracture of the hip, and subsequently transferred for coronary angiography because of ECG changes. An 81 year-old woman was admitted with pneumonia, and due to continued chest pain a coronary angiography was performed on the eleventh day. Three patients had normal coronary arteries, three had mild luminal irregularities and one had a non-significant stenosis distally in the ramus descendens anterior. Ventriculography was performed in four patients (Figure 1).

ECHOCARDIOGRAPHY

All patients had echocardiography performed during hospital stay. In three patients in whom ventriculography was not performed, LV apical ballooning was assessed by echocardiography. During the acute phase, all patients had mid-ventricular dysfunction and apical hypokinesis or akinesia. A transient dynamic intra-ventricular pressure gradient of 33 mmHg was demonstrated in one patient. This gradient had disappeared at follow-up echocardiography eight weeks later. Left ventricular systolic function was normalized at follow-up in all patients (Table 1).

CARDIAC BIOMARKERS

Elevated levels of tnT and CK-MB (Table 1) were observed in all patients. The mean peak (range) tnT and CK-MB were 1.7 (0.5-2.6) and 30 (10.8-46) µg/l, respectively.

DISCUSSION

The etiology of the TC has not been clearly established. Previous reports of the prevalence of TC vary depending on the selection of patients and the definition of the syndrome. In a few reports the prevalence of TC ranged 1-2% among patients presenting with a suspected STEMI [10-14], thus significantly higher than in the current study. This first Danish study of patients with TC confirms previously reported characteristics: a) approximately 90% of the patients are elderly women, b) in more than 50% of the cases an emotional or physical trigger event can be identified before onset of symptoms, c) symptoms most frequently are chest pain or dyspnoea [1, 2, 5, 14]. The clinical picture is, however, heterogeneous varying from fatigue, backache, dizziness, syncope to ventricular fibrillation and shock [2, 5, 14].

In the current study two of the seven patients were in a state of

cardiogenic shock and further three had transient clinical heart failure. No sustained malignant arrhythmias were identified.

Information about the temporal ECG changes in patients with TC is sparse. Our data indicate that the syndrome mimics STEMI with acute development, ST-elevation decreasing over days together with evolution of T-wave inversion and QTc prolongation. A previous report demonstrated a longer QTc three days after admission in patients with TC compared to QTc in patients with STEMI [4]. Q-waves in patients with TC may be present during the acute phase. Unlike most patients presenting with STEMI, this study indicates that Q-waves in patients with TC are transient. In general, normalization of the ECG is expected at follow-up. In accordance with previous findings [5, 6, 15] a discrepancy was demonstrated in the current study between the modest rise in cardiac biomarkers and the pronounced ECG changes and LV systolic dysfunction, respectively.

PATHOPHYSIOLOGICAL ASPECTS

When TC was initially described by Japanese groups the syndrome was interpreted as a demographical isolated syndrome [1, 2]. However, several case studies have been reported also in other ethnicities [4-6, 10, 12-14].

The etiology of TC has not been clearly established. Takotsubo cardiomyopathy is often provoked by emotional or physical stress and seems to represent a pathophysiological catecholamine effect on the myocardium mediated by a direct toxic effect or by a macro/microvascular dysfunction. This thesis is supported by the finding of elevated plasma catecholamine levels during the acute phase in more than 70% of patients with TC as compared to age-matched STEMI-patients [16]. Moreover, similar transient clinical, electrocardiographic and impairment of LV function have been demonstrated in patients with pheochromocytoma and catecholamine crisis [16-20]. An apical sympathetic innervation defect in patients with TC has been demonstrated by single photon emission computed tomography using ¹²³I-metaiodobenzylguanidine (MIBG) [17].

Sympathetic denervation of the heart leads to hypersensitivity to circulating ligands similar to what has been demonstrated in skeleton muscles [21]. A sympathetic denervation combined with an elevated β-receptor density in the apical myocardium [18] may hypothetically explain a condition in which a sudden rise in plasma catecholamines leads to regional LV stunning. This hypothesis also seems to explain the peculiar distribution of the functional LV disturbance.

Myocarditis has been proposed as a mechanism for the reversible LV dysfunction [19]. However, since cardiac magnetic resonance imaging does not show any sign of regional delayed hyperenhancement which is a stringent finding in myocarditis [19] the latter seems unlikely. A dynamic left ventricular outflow tract obstruction has been proposed in the pathogenesis of TC [1] which is secondary to a catecholamine induced intracardiac pressure gradient between the apical and the basal segments of the heart leading to elevation in wall stress, oxygen requirement, ischemia and therefore apical ballooning. Contradicting this theory is that the prevalence of an intraventricular gradient in patients with TC is reported in only about 16% of the studies [16]. In accordance, this study demonstrated the presence of an intracavitary pressure gradient in one out of seven patients.

Atypical forms of TC have been described with right ventricular involvement, and basal or mid-ventricular akinesia with or without apical hyperkinesis [16]. This variant form of TC might demand for reconsideration of the diagnostic criteria for this syndrome. Furthermore, in a recent animal study it was hypothesized that high levels of circulating catecholamines trigger a reversible switch in intracellular signal trafficking in ventricular cardiomyocytes from Gs protein to Gi protein signaling via β_2 -adrenoceptors causing a phenotype dependent regional negative inotropic response [20]. This hypothesis may have implications for the use of inotropic drugs in the treatment of patients with TC.

TREATMENT AND PROGNOSIS

In the acute phase, TC has clinical, electrocardiographic and echocardiographic characteristics indistinguishable from STEMI, thus acute coronary angiography is indicated in most cases. The current knowledge on the treatment of TC is deficient, but in light of the above mentioned catecholamine associated pathophysiological theory, treatment with adrenergic blocking agents, if tolerated, is potentially beneficial [16, 19].

In this report two patients were treated for cardiogenic shock. In one patient dobutamine was administered. The latter approach seems counterintuitive if TC is the result of a catecholamine mediated effect on the myocardium. Left ventricular ejection fraction was significantly lower in this patient as compared to the patient in whom dopamine was administered. An alternative haemodynamic support may be intraaortic balloon-pump counter-pulsation. One can consider short-term treatment with anticoagulation in order to prevent mural thrombus formation in patients with significantly reduced LV function. Although serious complications to TC are described, hospital mortality is low (0-8%), recurrence of the condition is rare and the long-term prognosis is favourable [10].

LIMITATIONS

The current study is limited by its retrospective nature and the small number of patients. The limited number of patients does not allow for statistical analysis. In this study it was not possible to determine the actual incidence of TC. Some TC cases may have been neglected because of: 1) a latency between symptom onset and the time of admission, 2) an echocardiography was not always performed in the acute phase, and 3) a ventriculography was not performed systematically in all patients with chest pain and a normal coronary angiography.

CONCLUSION

Danish patients with TC have clinical, electrocardiographic, biochemical and echocardiographic characteristics similar to what has been described in TC in other populations. As TC in the acute phase is indistinguishable from STEMI, acute coronary angiography usually is warranted. The ECG changes and the LV systolic function normalise within weeks to months. The pathophysiological mechanisms of TC have not been clearly established, but the syndrome appears to be mediated by a pathological catecholamine effect on the myocardium.

References

1. Dote K, Sato H, Tateishi H et al. Myocardial stunning due to simultaneous multivessel coronary spasms: a review of 5 cases. *J Cardiol* 1991;21:203-14.
2. Kurisu S, Sato H, Kawagoe T et al. Tako-tsubo-like left ventricular dysfunction with ST-segment elevation: a novel cardiac syndrome mimicking acute myocardial infarction. *Am Heart J* 2002;143:448-55.
3. Abe Y, Kondo M. Apical ballooning of the left ventricle: a distinct entity. *Heart* 2003;89:974-76.
4. Bybee KA, Kara T, Abhiram P et al. Transient left ventricular apical ballooning: a syndrome that mimics ST-segment elevation myocardial infarction. *Ann Internal Medicine* 2004;141:858-65.
5. Wittstein IS, Thiemann DR, Lima JA et al. Neurohumoral features of myocardial stunning due to sudden emotional stress. *N Engl J Med* 2005;352:539-48.
6. Bonnemeier H, Ortak J, Bode F et al. Modulation of ventricular repolarization in patients with transient left ventricular apical ballooning: a case control study. *J Cardiovasc Electrophysiol* 2006;17:1340-7.
7. Gianni M, Dentali F, Grandi AM et al. Apical ballooning syndrome or Takotsubo cardiomyopathy: a systematic review. *Eur Heart J* 2006;27:1523-9.
8. Hansen PR. [Stress induced "Takotsubo" cardiomyopathy: you can die from a broken heart!] *Ugeskr Læger* 2007;169:1209-11.
9. Maron BJ, Tawbin JA, Thiene G et al. Contemporary definitions and classifications of the cardiomyopathies. *AHA, Circulation* 2006;113:1807-16.
10. Bahlmann E, Schneider C, Krause K et al. Tako-Tsubo Cardiomyopathy Characteristics in long-term follow-up. *Int J Cardiol* 2008;124:32-9.
11. Matsuoka K, Okubo S, Fujii E et al. Evaluation of the arrhythmogenicity of stress-Induced "Takotsubo cardiomyopathy" from the time course of the 12-lead surface electrocardiogram. *Am J Cardiol* 2003;92:230-3.
12. Sharkey SW, Lesser JR, Menon M et al. Spectrum and significance of electrocardiographic patterns, troponin levels, and thrombolysis in myocardial infarction frame count in patients with stress (Tako-tsubo) cardiomyopathy and comparison to those in patients with ST-elevation anterior wall myocardial infarction. *Am J Cardiol* 2008;101:1723-8.
13. Parodi G, Del Pace S, Carrabba N et al. Incidence, clinical findings, and outcome of women with left ventricular apical ballooning syndrome. *Am J Cardiol* 2007;99:182-5.
14. Sharkey SW, Lesser JR, Zenovich AG et al. Acute and reversible cardiomyopathy provoked by stress in women from the United States. *Circulation* 2005;111:472-9.
15. Akashi YJ, Musha H, Kida K et al. Reversible ventricular dysfunction Takotsubo cardiomyopathy. *Eur J Heart Fail* 2005;7:1171-6.
16. Pilgrim TM, Wyss TR. Takotsubo cardiomyopathy or transient left ventricular apical ballooning syndrome : A systematic review. *Int J Cardiol* 2008 Mar 14;124:283-92.
17. Owa M, Aizawa K, Urasawa N et al. Emotional stress-induced 'apical cardiomyopathy': discrepancy between the metabolic and sympathetic innervation imaging performed during the recovery course. *Jpn Circ J* 2001;65:349-52.
18. Mori H et al. Increased responsiveness of left ventricular apical myocardium to adrenergic stimuli. *Cardiovasc Res* 1993;27:192-8.
19. Prasad A, Lerman A, Rihal CS. Apical ballooning syndrome (Tako-Tsubo or stress cardiomyopathy): a mimic of acute myocardial infarction. *Am Heart J* 2008;155:408-17.
20. Lyon A, Rees PSC, Prasad S et al. Stress (Takotsubo) cardiomyopathy – a novel pathophysiological hypothesis to explain catecholamine-induced acute myocardial stunning. *Nature Clin Prac Cardiovasc Med* 2008;5:22-9.
21. von Scheidt W, Bohm M, Schneider B, et al. Isolated presynaptic inotropic beta-adrenergic supersensitivity of the transplanted denervated human heart in vivo. *Circulation* 1992;85:1056-63.