

Sialoendoscopy for diagnosis and treatment of non-neoplastic obstruction in the salivary glands

Jacob Danquart¹, Niels Wagner¹, Helge Arndal¹ & Preben Homøe²

ABSTRACT

INTRODUCTION: The objective of this study was to evaluate our experience with sialoendoscopies for diagnosis and treatment of obstructive disease in the large salivary glands in Eastern Denmark and to broaden awareness of the procedure.

MATERIAL AND METHODS: A retrospective study was designed including the first 100 consecutive sialoendoscopies in 91 patients performed at Hillerød Hospital and Rigshospitalet, in the 2004-2009 period.

RESULTS: The median age of the 91 patients was 45 years (range 9-74 years) with a female-to-male ratio of 1.68. A total of 53 parotid and 47 submandibular endoscopies were performed. The indications for sialoendoscopy were sialolithiasis, stenosis, recurrent swelling and recurrent infections. We found an overall success rate of 91% in 100 diagnostic endoscopies and 62% in 65 interventional endoscopies. We observed an improvement in success rates over the course of the study period. Symptom relief was obtained in 69% of the patients with pathology following intervention. No serious complications occurred.

CONCLUSION: Sialoendoscopy is a safe, effective and minimally invasive method for diagnosis and treatment of obstructive salivary gland disease.

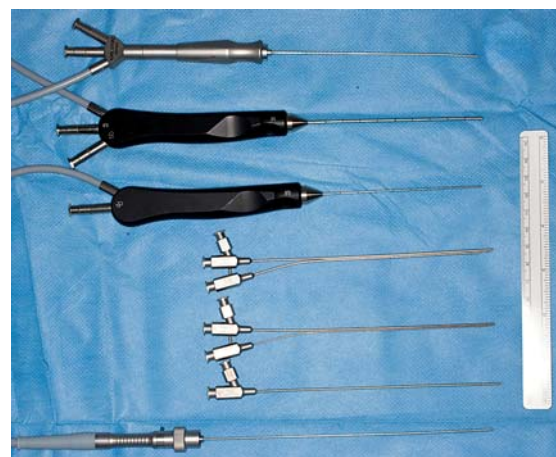
Sialoendoscopy is a relatively new method for the diagnosis and treatment of non-neoplastic obstructive disease in the submandibular and parotid glands. The technique has developed since the 1990s from blind stone removal and lithotripsy to the use of semi-rigid endoscopes with a working channel and high-quality imaging [1, 2]. Sialolithiasis was previously treated with either sialodochotomy or removal of the affected gland. The salivary flow is important for oral health as it protects mucus membranes and teeth, and lack of saliva may cause dental erosion, candida and ulceration. It is also of much importance to the patient's well-being including their quality of sleep. The removal of just one submandibular gland can cause relative xerostomia [3, 4]. Sialodochotomy involves a risk of postoperative stenosis of the duct and papilla, and open surgery on the salivary glands always involves a risk of facial nerve injury.

In sialoendoscopy, the lumen of Wharton's and Stensen's ducts and first and second branches can be

visualized. The duct of the submandibular gland has a diameter of between two and four millimetres and the parotid duct a diameter of one to two millimetres [5]. The technique allows for irrigation, dilation of the stenosis and removal of smaller sialoliths. The working channel of the endoscope facilitates the application of a guide wire, balloon catheter, wire basket, grasping forceps and laser fibres. The method is minimally invasive and allows preservation of the postoperative salivary flow [6]. It is now the second-choice treatment, ranked between conservative treatment with glandular massage, oral saliva stimulants, and antibiotics or surgical treatment with either sialodochotomy or surgical removal of the affected gland.

Sialoendoscopy comprises two elements; an initial diagnostic endoscopy followed by interventional endoscopy, where instruments are applied. Sialoendoscopy is performed while irrigating with saline to open the lumen and ensure overview. The procedure can be performed in either local or general anaesthesia.

In this article, we present a prospective retrospective study of the first 100 consecutive sialoendoscopies performed at the Ear, Nose and Throat (ENT) Department at Hillerød Hospital and the Department of Otolaryngology, Head and Neck Surgery at Rigshospitalet, Copenhagen University Hospital, Denmark, with the purpose of evaluating our experiences and expanding awareness of the procedure.



ORIGINAL ARTICLE

1) Ear, Nose and Throat Department, Hillerød Hospital, and 2) Department of Otolaryngology, Head and Neck Surgery, Rigshospitalet

Dan Med Bul 2011;58(2):A4232

Sialoendoscopes – combined instruments (top) with channels for irrigation and instruments. Sheaths with channels for endoscope, irrigation and instruments (bottom).

MATERIAL AND METHODS

This study was based on journal review of the first 100 consecutive sialoendoscopies performed in 91 patients at Hillerød Hospital and Copenhagen University Hospital in the 2004-2009 period. Demographic data including age and sex, preoperative symptoms and the use of preoperative imaging modalities were recorded. Operative findings were classified as sialolithiasis, stenosis, sialodochitis or any combination hereof. The use of local or general anaesthesia and complications were recorded. Successful diagnostic sialoendoscopy was defined as visualisation of normal findings in the duct and its primary and secondary branches or identification of pathology. In case of pathological findings, interventional endoscopy was performed if possible. Successful interventional sialoendoscopy was defined as treatment of the pathological findings. Symptoms at follow-up were divided into no symptoms, partial improvement or no change based on patient reports in the medical records.

The procedures were performed using Erlangen and Marchal sialoendoscopes (Karl Storz, Tuttlingen, Germany) ranging from a 0.9-mm diagnostic endoscope to a 1.7-mm endoscope with a working channel. The procedures were performed by four surgeons.

Ethics

The study was approved by the Danish Data Protection Agency and the Danish National Committee on Biomedical Research Ethics.

RESULTS

A total of 100 sialoendoscopies were attempted in 91

patients. Two patients had endoscopy of both the submandibular and parotid glands performed at separate occasions. Re-endoscopy was performed in seven cases. Four of the cases were due to problems with the introduction of the endoscope, one patient was re-scheduled for removal of a sialolith in general anaesthesia, one needed laser fragmentation of the encountered sialolith and one required re-endoscopy due to persisting symptoms. All re-endoscopies were successful. The indications for sialoendoscopy were sialolithiasis, stenosis, recurrent swelling and recurrent infections.

Demographic data and sialoendoscopy results are shown in **Table 1**.

In nine cases the affected submandibular gland was excised immediately following sialoendoscopy with the prior consent of the patients due to failure of diagnostic (3) or interventional endoscopy (5) and in one case with normal findings, but with clinical symptoms.

One of the above cases of failed diagnostic endoscopy was subsequently diagnosed with adenocarcinoma of the submandibular gland. One patient who had a parotid stone removed by combined approach was diagnosed with adenocarcinoma at the site of the removed sialolith eight months later and had a parotidectomy and neck dissection performed. Both patients were referred to the Oncology Department for further treatment.

Several imaging modalities were used in the preoperative assessment; some patients underwent more than one examination. Ultrasound was performed in 67 patients, X-ray of the floor of the mouth in 19, computed tomography of the head and neck in six, magnetic resonance imaging of the head and neck in three, and sialography in 12 patients.

A total of 67 cases of suspected sialolithiasis were discovered based on imaging and/or clinical assessment. Sialoendoscopy confirmed sialolithiasis in 41 of the 67 cases (61%). In the remaining 33 cases not suspected of sialoliths, sialolithiasis was found in four (12%). These four patients had recurrent swelling of the submandibular gland which was not associated with food intake prior to sialoendoscopy. In another four cases, stenosis was suspected and later confirmed by endoscopy. The remaining cases had swelling as the only distinctive preoperative finding.

Diagnostic endoscopies

Among the 100 diagnostic endoscopies performed, 91 were successful. There were normal findings in 14 cases, sialolithiasis in 38, stenosis in 30, a combination of sialolithiasis and stenosis in eight cases, as well as one case of sialodochitis.

Failure of diagnostic endoscopy was due to stenosis/scar tissue of the papilla (4) or suspicion of *via falsa* (5).



TABLE 1

Demographic data and sialoendoscopy results in 100 consecutive sialoendoscopies performed in the 2004-2009 period at the Ear, Nose and Throat Department, Hillerød Hospital, and the Department of Otolaryngology Head and Neck Surgery, Rigshospitalet.

<i>Patients, n</i>	91
Female	57
Male	34
F:M ratio	1.68
Median age, years (range)	45 (9-74)
<i>Sialoendoscopies, n</i>	100
Parotid	53
Submandibular	47
<i>Re-operations, n</i>	7
Parotid	6
Submandibular	1
<i>Anaesthesia, n</i>	100
General	88
Local	12

Figure 1 gives a flowchart overview of the 100 sialoendoscopies. Success rates in diagnostic and interventional endoscopies are found in **Table 2**.

Interventional endoscopies

Among the 77 successful diagnostic endoscopies in which pathology was detected, 12 cases were not suited for interventional endoscopy. In these cases, the duct was deemed too narrow for the interventional endoscope to access the stenosis (seven cases) and to access stone/stenosis (one case). Stone size was too large for removal in three cases, and, finally, no intervention was performed in the above-mentioned case of sialodochitis. A total of 65 interventional endoscopies were attempted of which 40 (62%) were successful (see Table 2). Stone removal was successful in 28 of 42 attempted cases (67%), one successful parotid stone removal was performed as a combined approach using sialoendoscopy for stone localisation and a modified facelift incision to access and remove the stone. Holmium laser treatment was applied in four stone removals. Dilatation of stenosis was attempted in 30 cases and was successful in 18 (60%). A stenosis was dilated to allow for stone removal in four cases.

Progress measured in terms of success rates in diagnostic and interventional sialoendoscopy from the first to the last 25 procedures is shown in Table 2.

In 14 cases, failure was attributable to the duct being so narrow that the interventional endoscope could not be introduced far enough to reach the pathology, and in eight cases the stone proved too large for removal.

Complications

During diagnostic endoscopy, *via falsa* arose in five cases. During intervention, one case of *via falsa*, one case of bleeding from the ductal wall and one case of the wire basket breaking in the duct all caused failure of the endoscopy.

Nine patients had signs of postoperative infection and were all treated successfully with antibiotics. Perioperative and postoperative antibiotics were not used on a routine basis, but prophylactic antibiotics were used in 30% of all sialoendoscopies.

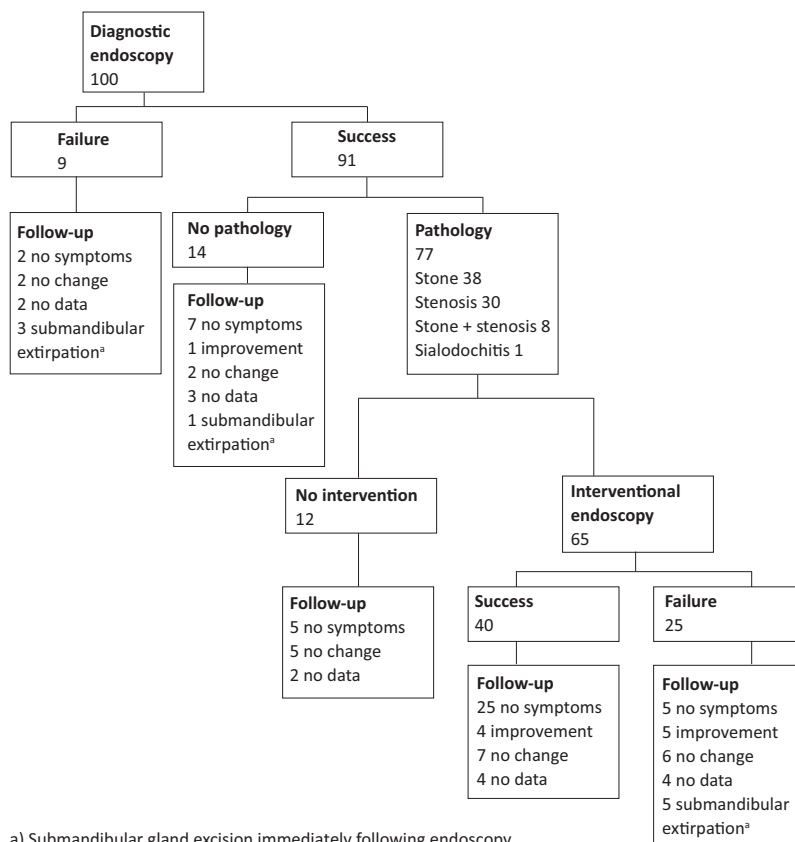
Among the patients who subsequently had their submandibular gland removed, one had postoperative paresis of the marginal branch of the facial nerve, but this was not attributed to the sialoendoscopy.

Follow-up

We had follow-up data from 76 of 82 (93%) patients, excluding the nine patients who had their submandibular gland removed. The median follow-up time was four months (range 1 week-40 months). Symptoms at follow-up are listed in **Table 3**.

FIGURE 1

Results of 100 consecutive sialoendoscopies performed in the 2004-2009 period at the Ear, Nose and Throat Department, Hillerød Hospital and the Department of Otolaryngology Head and Neck Surgery, Rigshospitalet.



a) Submandibular gland excision immediately following endoscopy.

DISCUSSION

Sialoendoscopy has changed the management of obstructive salivary gland disease in recent years and sialoendoscopy may now involve stone removal, dilatation of stenosis and irrigation of the salivary ducts in certain inflammatory diseases. The procedure has been validated in large patient materials where focus has been on the parotid as well as the submandibular gland. This also involves paediatric sialoendoscopy [2, 7-9]. Sialoendoscopy is now available in certain ear-nose-throat departments across Denmark.

Our study confirms that sialoendoscopy is a safe and effective method for the diagnosis and treatment of obstructive diseases of the large salivary glands. The option of performing the procedure in local anaesthesia makes sialoendoscopy attractive even in outpatient settings.

We found a success rate for diagnostic endoscopy of 91%. Sixty-five interventional endoscopies were performed with a success rate of 62%. Eight failures were caused by stones that proved too large to be removed

TABLE 2

Sialoendoscopy success rates in 100 consecutive diagnostic and 65 interventional sialoendoscopies and development in success rates from the first to the final 25 diagnostic and interventional endoscopies performed in 2004-2009 at the Ear, Nose and Throat Department, Hillerød Hospital, and the Department of Otolaryngology Head and Neck Surgery, Rigshospitalet.

	n	Success rate, % (95% CI)
<i>Diagnostic endoscopy</i>	100	91 (85.4-96.6)
Parotid	53	96 (90.7-100)
Submandibular	47	85 (74.8-95.2)
<i>Interventional endoscopy</i>	65	62 (50.2-73.8)
Parotid	36	64 (48.3-79.7)
Submandibular	29	59 (41.1-76.9)
<i>First 25 sialoendoscopies</i>		
Diagnostic endoscopies	–	92 (82.8-100)
<i>Final 25 sialoendoscopies</i>		
Diagnostic endoscopies	–	100 (100)
Interventional endoscopies	–	71 (53.2-88.8)

CI = confidence interval.

TABLE 3

Symptoms at follow-up in 76 patients divided into no symptoms, partial improvement and no change according to success or failure of sialoendoscopy in 2004-2009 at the Ear, Nose and Throat Department, Hillerød Hospital, and the Department of Otolaryngology Head and Neck Surgery, Rigshospitalet.

	n (%)			
	total	no symptoms	partial improvement	no change
<i>Diagnostic endoscopy only</i>	14			
Failure	4	2 (50)	1 (25)	1 (25)
Normal findings	10	7 (70)	2 (20)	1 (10)
<i>Pathology found</i>	62			
Successful intervention	36	25 (69.4) ^a	4 (11.1) ^a	7 (19.4) ^a
Failure of intervention	16	5 (31)	5 (31)	6 (38)
Diagnostic endoscopy only	10	5 (50)	–	5 (50)

a) Percentages were rounded down.

with the equipment at hand, which also caused us to refrain from intervention after the diagnostic endoscopy in four cases. Smaller endoscopes and equipment allowing for laser fragmentation could have solved some of these problems. Furthermore, a combined approach technique was not used until the end of this study. We believe that the introduction of new equipment and increased experience may contribute considerably to a rise in success rates. There seems to be a steep learning curve before surgeons master the procedure, and we anticipate that local anaesthesia will be the method of choice in the period during which the endoscopists are gaining more experience and new and even more versatile endoscopes are being introduced. As seen in Table 2, the success rates rose from the first 25 procedures to the final 25 procedures, although not significantly. Our final diagnostic success rate is similar to the success rates previously reported by Marchal & Duelgerov (98%)

and Nahlieli et al (96%) who used similar definitions of success [2, 8]. Our overall interventional sialendoscopy success rate of 62% is somewhat lower than the rates reported by the above-mentioned authors whose interventional success rates reached 82-92% [8, 10, 11]. Postoperative infections occurred in 9% of the cases. Given that 30% of the patients received prophylactic antibiotics, perioperative antibiotics should be considered. One wire basket broke during interventional endoscopy, but as the patient had no symptoms at follow-up, a planned submandibular extirpation was cancelled. There were no other serious complications due to the endoscopies.

Symptom relief was reported in 69% of the patients with obstructive pathology in whom successful interventional sialendoscopy had been performed, and in 54% of all patients who had had an endoscopy (data not shown). In our study, sialoendoscopy with normal findings produced symptom relief in 70% and partial improvement in 20% of the patients. A likely explanation for this is that dilation of the papilla, irrigation of the ducts and the dilating effect of the endoscopy itself offer sufficient treatment in some cases. Longer follow-up is needed to clarify this. In line with the above result, 50% of the patients who only had a diagnostic endoscopy performed experienced complete symptom relief even though no treatment was executed for the pathology found. As this became clear, we abandoned excision of the submandibular gland immediately following failure of endoscopy. Furthermore, we found stenosis in 38/77 (49%) patients with pathology. Along with the above findings, this indicates that stenosis is a frequent pathological finding, which is seemingly underdiagnosed before surgery. It should be noted that we did not differentiate between types of stenosis in the present study, which may account for the high occurrence compared with previous reports [12, 13]. Preoperative assessment is difficult and controversial. Underlying malignancy in the chronically swollen gland must be kept in mind. Follow-up is standard in the recording of outcome and symptom recurrence. In our study, a discrepancy was found between preoperative assessment and operative findings in patients suspected of sialolith-related disease. This has also previously been reported [2, 8].

A guideline for preoperative assessment and a standardisation of the clinical examination is needed. Differences in the availability of imaging modalities are profound. We propose that ultrasound be considered the first-choice modality, given that it is more easily available and less expensive than computed tomography and magnetic resonance imaging. At present, ultrasound, including stone size measurement, can be performed at most ENT departments.

CONCLUSION

Sialoendoscopy is a safe, effective and minimally invasive method for the diagnosis and treatment of non-neoplastic obstructive disease in the large salivary glands. The procedure is now available at certain ENT departments across Denmark. The procedure should only be performed at a limited number of centres to ensure a sufficient patient flow and sufficiently experienced sialoendoscopists. Sialoendoscopy is now considered the second choice following conservative treatment in obstructive non-neoplastic salivary gland disease. Dilation of the papilla and sialoendoscopy and irrigation may in itself alleviate the symptoms in an otherwise normal endoscopy and the gland should therefore not be immediately excised in the same procedure. Further studies are needed to evaluate the long-term effects of sialoendoscopy.

CORRESPONDENCE: *Jacob Danquart*, Bakkedraget 16, 2. tv., 3400 Hillerød, Denmark. E-mail: jacob@danquart.dk

ACCEPTED: 15 November 2010

CONFLICTS OF INTEREST: As a faculty member, *Preben Homøe* has attended the 12. Sialoendoscopy Course held 9-11 October, 2008 in Geneva. The course was supported by Karl Storz GmbH, Germany. Karl Storz are producers and manufactures of the equipment needed for sialoendoscopy. Course and travel expenses were paid. However, this was unrelated to the present manuscript.

LITERATURE

1. Koch MJ, Zenk J, Iro H. Algorithms for treatment of salivary gland obstructions. *Otolaryngol. Clin North Am* 2009;42:1173-92.
2. Marchal F, Duelgerov P. Sialolithiasis management: the state of the art. *Arch Otolaryngol Head Neck Surg* 2003;129:951-6.
3. Cunning DM, Lipke N, Wax MK. Significance of unilateral submandibular gland excision on salivary flow in noncancer patients. *Laryngoscope* 1998;108:812-5.
4. Jacob RF, Weber RS, King GE. Whole salivary flow rates following submandibular gland resection. *Head Neck* 1996;18:242-7.
5. Zenk J, Hosemann WG, Iro H et al. Diameters of the main excretory ducts of the adult human submandibular and parotid gland: a histologic study. *Oral Surg Oral Med Oral Pathol Oral Radiol Endod* 1998;85:576-80.
6. Su YX, Xu JH, Liao GQ et al. Salivary gland functional recovery following sialendoscopy. *Laryngoscope* 2009;119:646-52.
7. Martins-Carvalho C, Plouin-Gaudon I, Quenin S et al. Pediatric sialendoscopy: a 5-year experience at a single institution. *Arch Otolaryngol Head Neck Surg* 2010;136:33-6.
8. Nahlieli O, Nakar LH, Nazarian Y et al. Sialoendoscopy: a new approach to salivary gland obstructive pathology. *J Am Dent Assoc* 2006;137:1394-400.
9. Shacham R, Droma EB, London D et al. Long term experience with diagnosis and treatment of recurrent juvenile parotitis. *J Oral Maxillofac Surg* 2009;67:162-7.
10. Marchal F, Duelgerov P, Becker M et al. Submandibular diagnostic and interventional sialendoscopy: a new procedure for ductal disorders. *Ann Otol Rhinol Laryngol* 2002;111:27-35.
11. Marchal F, Duelgerov P, Becker M et al. Specificity of parotid sialendoscopy. *Laryngoscope* 2001;111:264-71.
12. Nahlieli O, Shacham R, Yoffe B et al. Diagnosis and treatment of strictures and kinks in salivary gland ducts. *J Oral Maxillofac Surg* 2001;59:484-90.
13. Ardekian L, Shamir D, Trabelsi M et al. Chronic obstructive parotitis due to strictures of Stenson's duct – our treatment experience with sialoendoscopy. *J Oral Maxillofac Surg* 2010;68:83-7.