

Tympanotomy and sealing of the round window for treatment of sudden deafness

Jamshaid Ul-Mulk¹, Søren Friis¹ & Christoffer Holst Hahn²

ABSTRACT

INTRODUCTION: The objective of this study was to evaluate the effectiveness of explorative tympanotomy and sealing of the round window in patients diagnosed with sudden deafness.

MATERIAL AND METHODS: A retrospective study of 22 patients presenting with sudden deafness who were treated with explorative tympanotomy and sealing of the round window. The patients initially received conservative therapy for one month. If conservative treatment had no effect, explorative tympanotomy and sealing of the round window was performed.

RESULTS: The median pure tone average was 67 dB before surgery. Post-operatively, it was reduced to 55 dB. This is equivalent to a 12 dB ($p = 0.008$) improvement. Five patients improved beyond 30 dB and three patients out of 22 fulfilled the Belfast criteria for binaural hearing at the end of the observation period. Furthermore, three months after surgery, the incidence of vertigo and tinnitus had decreased from 58% to 8% and from 50% to 17%, respectively ($p < 0.001$ and $p = 0.04$). None of the patients experienced any severe or life-threatening complications.

CONCLUSION: The results suggest that explorative tympanotomy and sealing of the round window may improve hearing and reduce tinnitus and vertigo after spontaneous remission has come to an end. However, randomized controlled studies are needed.

FUNDING: not relevant.

TRIAL REGISTRATION: not relevant.

Hearing loss is a common phenomenon. Sudden deafness (SD) constitutes about 3% of these cases. However, treatment of SD is controversial and even today there is no well-documented treatment [1, 2]. SD was described by De Kleyn in 1944 and is defined as an acute hearing loss equal to or exceeding 30 decibel (dB) in three contiguous frequencies occurring within three days [1, 2].

The diagnostic criteria are as follows: a) presence of the following three main symptoms: 1) acute appearance, 2) sensorineural hearing loss and 3) unknown aetiology. These main symptoms can be accompanied by three accessory symptoms: 1) vertigo, 2) tinnitus or nausea or 3) no cranial nerve symptoms [3, 4].

The incidence for SD is 5-30/100,000 person years. The sex distribution is equal and the peak age is 50-60 years. Vestibular symptoms are present in 28-57% of patients [1, 4, 5].

The aetiology of SD is unknown. However, several pathophysiological mechanisms have been proposed, for example infectious causes (varicella-zoster, herpes zoster, etc.), vascular causes, autoimmune causes, changes in the pressure of the endolymph and perilymphatic fistula. None of these theories are well-documented [1, 2, 4].

The spontaneous recovery rate lies in the 50-70% range. Compared with hearing loss in middle and high frequencies, low-frequency SD has a better prognosis with an expected spontaneous recovery rate of 80% [5-7].

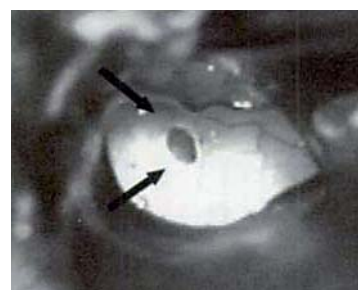
Perilymphatic fistula with rupture of the round window is considered the aetiology in some SD cases. The frequency of perilymphatic fistula as a cause of SD is controversial. Moreover, perilymphatic fistula is a very difficult diagnosis to make. A definite diagnosis can only be made by explorative tympanotomy where liquor is seen oozing. In Denmark, it is generally considered that the frequency of perilymphatic fistula is very low for SD. Explorative tympanotomy is therefore not a common part of the treatment for SD, except for barotrauma. For a number of years, the Department of Ear, Nose and Throat (ENT), Head and Neck Surgery at Næstved Hospital has considered perilymphatic fistula to be an important cause of SD [3, 8]. Consequently, explorative tympanotomy has been offered to patients with SD whose symptoms did not disappear within three weeks.

With the aim of evaluating the effectiveness of this treatment, all cases of SD that were treated with explorative

ORIGINAL ARTICLE

1) Department of Ear, Nose and Throat, Head and Neck Surgery, Næstved Hospital, and 2) Department of Ear, Nose and Throat, Head and Neck Surgery, Gentofte Hospital

Dan Med Bul
2011;58(5):A4276



Perilymphatic fistula marked by arrows.

ative tympanotomy at Næstved Hospital between 2001-2009 were analyzed retrospectively.

MATERIAL AND METHODS

Between 2001 and 2009, exploratory tympanotomy was carried out in 22 patients who were diagnosed with SD at The Department of ENT, Head and Neck Surgery at Næstved Hospital. Four patients (18%) had SD after head trauma. None of our patients had SD because of pressure alterations due to diving or flying.

The majority of patients (68%) had a hearing loss exceeding 60 dB. At first, all patients were followed for one month to rule out spontaneous recovery of the hearing loss. Four patients (18%) had received oral prednisolone treatment 50 mg once daily for seven days. Since conservative therapy had no effect on the hearing loss, exploratory tympanotomy was carried out. One patient was operated after 12 days.

All operations were carried out by the same surgeon. The procedure began with a Rosen incision. The tympanomeatal flap was prepared. The round window was identified and observed for leak of clear fluid. Fluorescein was not used to prove the leaking. The procedure was the same in every operation and every time it was followed by denudating around the round window, even though leaking was not observed. Furthermore, the round window was enhanced with fat and connective tissue and, finally, it was kept in place by spongostan and fibrin.

An audiogram was obtained the day before surgery and another three months after the operation. Pure tone average for air conduction was calculated from the

frequencies 500, 1,000, 2,000 and 4,000 Hz. The median age was 53 years (range 19-66).

Medical history, blood tests, otological and neurological examination were performed and magnetic resonance imaging of the brain was also performed on 13 of the patients. Two of the patients had a computer tomographic scan of the brain. None of the patients had acoustic neuroma.

Statistics

Pre- and post-operative pure tone averages were normally distributed according to Shapiro-Wilk.

T-test was paired for comparison. Pre- and post-operative vertigo and tinnitus were compared using the chi-square test.

Trial registration: not relevant.

RESULTS

Twenty-two patients were identified, 12 (55%) of whom were male and ten (45%) women. The right ear was involved in 12 (55%) cases and the left ear in ten (45%) cases.

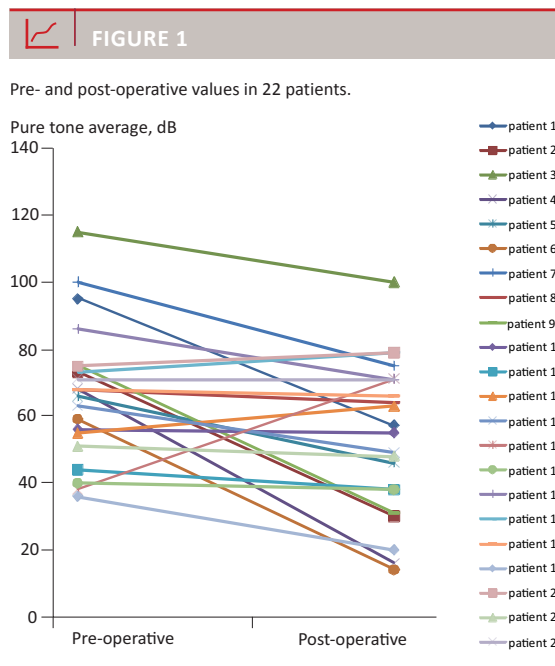
The mean value of the pure tone average before surgery was 67 dB (13 on the healthy ear). After surgery the average threshold was 55 dB. This is a 12-dB ($p = 0.008$) improvement. The improvement covers a heterogeneous patient group: four patients experienced no improvement, while three experienced complete remission (**Figure 1**). A total of 18 patients had a measurable hearing improvement. Only five patients improved beyond the clinically important 30-dB hearing aid limit. Three patients improved to meet the "Belfast rule of thumb" criteria [9, 10] of both air conduction ≤ 30 dB and interaural difference ≤ 15 dB, which indicates full recovery to binaural hearing.

A total of 58% of the patients complained about vertigo before surgery. Three months after surgery, the number had fallen to 8% ($p < 0.001$). A total of 50% experienced tinnitus before surgery. After surgery, only 17% had tinnitus ($p = 0.04$).

None of the patients experienced any severe and/or life-threatening post-operative complications. They were all discharged from the hospital 1-2 days after surgery.

DISCUSSION

In the 22 patients, hearing improved during the three months following explorative tympanotomy and sealing of the round window membrane in patients with SD. During this period, vertigo and tinnitus decreased in these patients. The results are in accordance with earlier retrospective studies by Gedlicka et al [3] and Maier et al [8]. Gedlicka and colleagues had a population of 60



patients who were diagnosed with idiopathic sensorineural hearing loss. All patients were treated with prednisolone and if this conservative treatment was not effective, a tympanotomy with sealing of the round window was performed. In 40 (67%) of the cases, complete remission of the hearing loss was observed. Twenty (33%) patients experienced no improvement of their hearing loss. Maier and colleagues performed a study of 97 cases who experienced an improvement of their hearing loss of up to 40 dB in the low frequencies and up to 20 dB in the middle and high frequencies after explorative tympanotomy.

Tinnitus and vertigo generally improve with time. This study shows improvement of tinnitus and dizziness that may be attributed to spontaneous remission. Hearing is usually not improved three weeks after SD. This study is of relevance because some of the patients showed improved hearing after three weeks. In Denmark, there is no established treatment for SD. Patients at Næstved Hospital were offered explorative tympanotomy to diagnose and treat perilymphatic fistula, which resulted in improved hearing. Some patients' hearing did not improve from surgery because they had no perilymphatic fistula. The problem with perilymphatic fistula is that diagnosing is difficult. Sometimes, perilymphatic leakage from the round window is not visible when explorative tympanotomy is performed. All patients with SD were therefore offered explorative tympanotomy with sealing of the round window.

A major weakness of the present study is that only 22 patients were studied and that there was no control group for comparison. If spontaneous remission was disregarded entirely and all hearing improvement attributed to the effect of surgery, three to five of the 22 patients would seem to have achieved a clinically significant improvement from the surgical treatment. However, the potential for further spontaneous improvement during 1-4 months after the development of SD is unknown. Furthermore, in the present study, an audiogram was not performed six and 12 months after surgery. Simmons [11] describes that it is not suitable to carry out an early tympanotomy as it will reduce the chance of inner ear healing, because surgery induces a new trauma to the ear. Hence, tympanotomy should be performed after ten days if there is no improvement of the hearing loss or escalation of the vestibular symptoms [12].

This study also shows that explorative tympanotomy is a safe procedure. None of the patients experienced any life-threatening complications. Several studies have documented that one of the possible causes for SD is perilymphatic fistula. This condition is difficult to diagnose, but when explorative tympanotomy is performed, it is easier to diagnose and it can be treated by surgery [8].

The treatment of SD is controversial. Over the past few years, oral prednisolone treatment has become a standard in many countries [2, 7]. Prednisolone is supposed to have many effects on the inner ear. Suppression of an immune response, changes in microvascular circulation and reduction of the endolymphatic pressure are some of the theories [1]. A recent Cochrane review concluded that the value of steroids remains unclear since the evidence obtained from randomized controlled trials is contradictory in outcome. This is partly so because the studies were based upon a small number of patients [1-5, 7]. Intratympanic dexamethasone treatment has also been tried on patients with SD. It induces a high concentration of dexamethasone in the inner ear. A randomized placebo-controlled trial in which one group received oral prednisolone, intratympanic dexamethasone or both showed a more pronounced improvement in the hearing in the group that received combination treatment. But evidence is still lacking and contradictory. A systematic Cochrane study is under way to test evidence of these theories [1-2, 5]. Furthermore, treatment with methotrexate, antiviral agents (e.g. acyclovir), aspirin and hyperbaric oxygen treatment in clinical trials has been tried with no significant effect [1].

In conclusion, there is no consensus on the treatment of patients diagnosed with SD. General recommendations do exist. This study shows that hearing improves significantly in patients diagnosed with SD to whom an explorative tympanotomy and sealing of the round window is performed one month after disease onset. Furthermore, vertigo and tinnitus disappears in the majority of patients during the three months following surgery. This study includes a small number of patients and the design is retrospective with no control group. A randomized clinical trial is therefore recommended in order to further elucidate this matter.

CORRESPONDENCE: Jamshaid Ul-Mulk, Kirurgisk Afdeling, Rigshospitalet, Blegdamsvej 9, 2100 Copenhagen Ø, Denmark.
E-mail: mulkomania@hotmail.com

ACCEPTED: 17 march 2011

CONFLICTS OF INTEREST: Disclosure forms provided by the authors are available with the full text of this article at www.danmedbul.dk

ACKNOWLEDGMENT: Special thanks to secretary *Stine Idom Osted Nielsen* who has been very kind to help find the patient lists and journals.

LITERATURE

- Schreiber B, Agrup C, Haskard H et al. Sudden sensorineural hearing loss. *Lancet* 2010; 375:1203-11.
- Conlin A, Parnes L. Treatment of sudden sensorineural hearing loss. A systematic review. *Arch Otolaryngol Head and Neck Surg* 2007;133: 573-81.
- Gedlicka C, Formanek M, Ehrenberger K. Analysis of 60 patients after tympanotomy and sealing of the round window membrane after acute unilateral sensorineural hearing loss. *Am J Otolaryngol Head Neck Med Surg* 2009;30:157-61.
- Suckfüll M. Perspectives on the pathophysiology and treatment of sudden idiopathic sensorineural hearing loss. *Dtsch Arzbeil Int* 2009;106:669-76.
- Rauch S. Clinical practice. Idiopathic sudden sensorineural hearing loss. *N Eng J Med* 2008;359:833-40.
- Zadeh M, Stoper I, Spitzer J. Diagnosis and treatment of sudden-onset sensorineural hearing loss: A study of 51 patients. *Otolaryngol Head Neck Surg* 2003;128:92-8.

7. Finger R, Gostian A. Idiopathic sudden hearing loss: contradictory clinical evidence, placebo effects and high spontaneous recovery rate – where do we stand in assessing treatment outcomes. *Acta Otolaryngol* 2006;126:1124-7.
8. Maier W, Fradis M, Kimpel S et al. Results of exploratory tympanotomy following sudden unilateral deafness and its effect on hearing restoration. *Ear Nose Throat J* 2008;87:438-51.
9. Smyth GDL, Patterson CC. Results of middle ear reconstruction: Do patients and surgeons agree? *Am J Otol* 1985;6:276-9.
10. Toner JG, Smyth GDL. Comparison of methods of evaluating hearing benefit of middle ear surgery. *J Laryngol Otol* 1993;107:4-5.
11. Simmons F. The double-membrane break syndrome in sudden hearing loss. *Laryngoscope* 1979;89:59-66.
12. Freemann R. Rupture of the round window membrane. *Acta Otolaryngol (Belg)* 1975;29:783-94.