

Using a double-layered palmaris longus tendon for suspension of facial paralysis

Navid Mohamadpour Toyserkani, Vivi Bakholdt & Jens Ahm Sørensen

ABSTRACT

INTRODUCTION: Facial palsy is a debilitating condition entailing both cosmetic and functional limitations. Static suspension procedures can be performed when more advanced dynamic techniques are not indicated. Since 2006, we have used a double-layered palmaris longus tendon graft through an ovular skin excision in the nasolabial fold for access. The aim of this paper is to present our surgical technique and case series.

METHODS: This study was a retrospective case series in a university hospital setting. All patients who had this procedure performed were included before August 2013. Data from electronic patient records were retrieved, patients were invited for a follow-up visit and results were measured using the Lip Reanimation Outcomes Questionnaire. Furthermore, standardised photographs were taken and evaluated by multiple surgeons.

RESULTS: A total of 13 patients were included with a mean follow-up of 49 months (range: 3-89 months). 93% noted an improvement of their facial appearance at follow-up. Seven out of 11 patients with preoperative problems with speech noted an improvement at follow-up. Eight out of 12 patients with preoperative problems with oral competence noted an improvement at follow-up. Photographic evaluation revealed an acceptable symmetry at rest with an increasing asymmetry with increasing smile intensity. No post-operative complications or donor site morbidity was noted in any of our patients.

CONCLUSION: Our technique is easy to perform with no noteworthy complications, and it improves the quality of life of patients with facial palsy. It is an acceptable alternative when more advanced procedures are not indicated.

FUNDING: not relevant.

TRIAL REGISTRATION: not relevant.

Facial nerve paresis/paralysis is a debilitating condition that entails both cosmetic and functional deficits with great impact on quality of life [1, 2].

Several techniques have been developed to address the appearance and functional limitations of patients with lasting sequelae of facial nerve paresis/paralysis. Such treatments include both dynamic reanimation techniques and static suspension procedures. Static procedures can be applied to patients who are not candidates for dynamic reanimation procedures (i.e. due to

severe co-morbidity, old age or lack of interest on the part of the patient who just requests an immediate fix), but who would still benefit from the restoration of facial symmetry at rest [3].

Several different options exist for suspension material such as acellular human dermis [4], expanded polytetrafluoroethylene [5], sutures [6] and autologous tissue such as fascia [7] or tendon grafts [8, 9]. Ibrahim et al [10] recently summarised static treatment options in general for facial palsy. Over a period of years, we have developed a technique using a double-layered palmaris longus tendon graft for static suspension in a combination with an ovular skin excision in the nasolabial fold. To our knowledge, this approach has not previously been described. In this paper, we describe our technique and briefly present our case series from the period May 2006 to August 2013.

METHODS

This study was conducted as a retrospective case series in a university hospital setting. All patients from May 2006 to August 2013 with facial paralysis who underwent static suspension using our described technique were invited for a follow-up visit in November 2013. All patients were either not interested in more advanced surgery or such surgery was deemed not indicated by the department of plastic surgery because of old age and/or severe co-morbidity. The electronic patient record was reviewed for demographic and surgical data, including age at time of surgery, gender, primary disease, days to discharge and complications.

Outcome was measured using the Lip Reanimation Outcomes Questionnaire (LROQ), which is a validated 15-item questionnaire designed for retrospective outcome evaluation [11] (Appendix 1). With this questionnaire, preoperative symptom severity is graded with seven-point-scale questions and post-operative change is graded with a seven-point Likert scale. The questionnaire also includes a visual analogue scale (VAS) where the patient is asked to assess his or her smile symmetry. Standardised photographs were taken by a clinical photographer using a Nikon D3 camera with a Nikon AF-S VR Micro-Nikkor 105mm f/2.8 IF-ED objective and an Elinchrom BX-100 Studioflash with a white transparent diffuser.

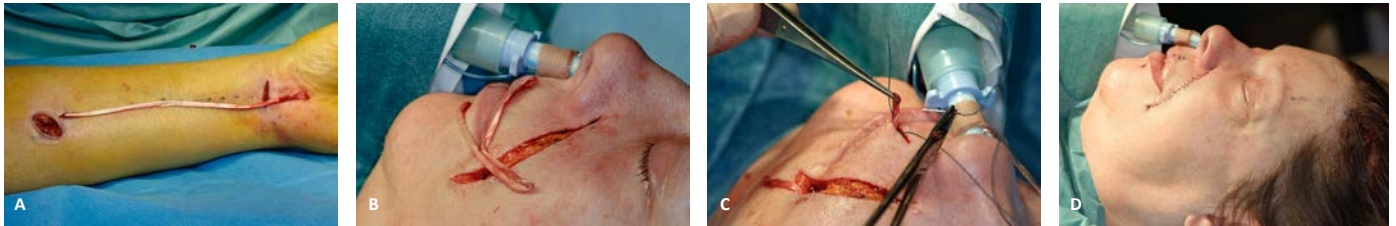
ORIGINAL ARTICLE

Department of Plastic and Reconstructive Surgery, Odense University Hospital

Dan Med J
2015;62(3):A5021

 FIGURE 1

Intraoperative photographs. **A.** The palmaris longus tendon is harvested through two incisions on the forearm with a tendon harvester. **B.** The oval skin excision in the nasolabial fold has been made and the placement of the double-layered tendon is shown. **C.** Each leg of the tendon is sutured to innervated muscle on the opposite side on the lower and upper lip. The end of the tendon is sutured to the periosteum of the malar part of zygoma with an appropriate tension and vector. **D.** The skin is closed conventionally in two layers. This patient had concomitant forehead lift.



The patient was photographed at rest and with three different smile poses (Mona Lisa, Canine and Full mouth). Photographs were independently assessed by two consultants in plastic surgery and one surgical trainee as part of the LROQ, where asymmetry severity was assessed on a seven-point scale.

All subjects provided informed consent and all photographs shown in this paper have been accepted by the patients. Ethical approval was not needed for this study.

Statistical analysis was performed with IBM SPSS Statistics 20. The Pearson correlation coefficient was used to examine the correlation between ratings from physician- and patient-rated symmetry.

Surgical technique

The palmaris longus tendon is harvested using a tendon-harvester through two 1 cm incisions; one just above the wrist crease and the other where the muscular belly of the palmaris longus starts. The tendon is harvested in full length.

An oval skin excision is made in the nasolabial fold in order to imitate the contralateral fold. This excision gives easy access to the areas of interest, upper and lower lip and to the malar part of the zygoma. The tendon is folded in a double-layered fashion, and the central portion is sutured to the periosteum of the malar part of the zygoma with non-resorbable braided sutures (Ethicon Mersilene 2-0). Each leg of the tendon is then placed in a pocket in the upper and lower lip, respectively, and sutured to innervated muscle on the contralateral side with non-resorbable braided sutures (Ethicon Mersilene 2-0) through small incisions in the philtrum. The two legs of the tendon are connected with the angle of the mouth with an appropriate tension (minimal over-tightening about an extra 1cm of upward smile when compared with neutral contralateral side) that mimics the others side at rest, also with non-resorbable braided sutures (Ethicon Mersilene 2-0). The most important suture is to the corner of the mouth, but securing the tendon to the

innervated contralateral muscle increases the balance of the mouth and reduces the risk of elongation of the paralysed side. The skin is closed conventionally in two layers. Aftercare is limited to 2 days of liquid feeding and another 8 days of soft diet and gradually increasing solid food intake (see **Figure 1** for intraoperative pictures).

Trial registration: not relevant.

RESULTS

In total, 19 patients had static facial suspension performed from May 2006 onwards. Five patients were dead at our follow-up, and one patient did not have the palmaris longus tendon; a fascia lata graft was used instead and this patient was therefore excluded. This left 13 patients, all of whom came for a follow-up visit. There were 7 male and 6 female patients with an average age at surgery of 65.2 years (median = 62 years, range: 57-78 years). The average follow-up time was 49 months (range: 3-89 months). Seven patients had concomitant eyelid or eyebrow surgery. The average number of days to discharge from hospital was 1.6 days (range: 1-3 days, median = 1.5 days). Three patients underwent later revision surgery. One required tightening of the suspension, another scar revision and the last revision had lipofilling to the cheek. Four out of the five who had died during follow-up died with disseminated cancer of different origins and one died of stroke.

Twelve patients felt that their facial appearance had improved post-operatively at follow-up and only one patient felt it had deteriorated over time. Twelve patients had problems with oral continence before surgery and eight reported an improvement at follow-up. One patient felt it had become worse with time. All patients suffering from oral incontinence experienced problems with liquids, 75% had problems with saliva and 58% had problems with solid foods. Eleven reported problems speaking clearly before surgery and seven of these reported an improvement at follow-up. One patient felt it

had become worse with time. See **Table 1** for a summary of the LROQ questionnaire results. It was the same patient who felt all domains had become worse both aesthetically and functionally.

Photographic evaluation revealed an acceptable facial symmetry in neutral position. However, an increased asymmetry was seen with increasing smile intensity (see **Table 2**). Using a visual analogue scale, patients rated their current smile at 3.3 (median = 2.7, range: 1.4-6.3) (1 = very asymmetric and 10 very symmetric). See **Figure 2** for examples of post-operative results.

There was no correlation between patient self-rated symmetry and the mean evaluation of symmetry of the three physicians ($r = -0.17$, $p > 0.05$). The correlations between the resident and the two plastic surgery consultants were statistically significant ($r = 0.59$, $p < 0.05$, and $r = 0.76$, $p < 0.01$). The correlation between the two consultants was not statistically significant ($r = 0.36$, $p > 0.05$).

No post-operative complications were noted in any of our patients. No donor site morbidity was noted.

DISCUSSION

We have presented our preferred technique for static facial reanimation using the double-layered palmaris longus tendon in a combination with an ovular skin excision in the nasolabial fold. We have had no complications with this procedure. Previously, this type of suspension was performed through a facelift incision. This incision leaves the scar well concealed but the access to upper and lower lip and the corner of the mouth is quite difficult, and in our follow-up of our patients we observed that many of them had a very diminished nasolabial fold. We tried to enhance the nasolabial fold by placing an ovular skin excision in the nasolabial fold and the following scar, and the excised skin helped to accentuate this facial landmark. This scar never seemed to cause any problems, and some patients even requested additional skin excision in the area. We therefore abandoned the facelift incision and made an ovular excision in the nasolabial fold in order for the scar to imitate the nasolabial fold on the contralateral side. This provided a higher degree of facial symmetry at rest and made the surgical procedure much faster. In some patients, a severe lack of bulk in the paralysed side will result in a flattened/diminished nasolabial fold, but even in these cases the scar helps to mark the transition to the cheek. Scars in this area are very inconspicuous, and skin excisions in this area are also performed for aesthetic reasons [12]. The limitations of this procedure are revealed with increasing smile intensity as it is a static procedure that only provides symmetry at rest.

The goal of the procedure is to achieve facial symmetry at rest and to improve oral competence and

TABLE 1

Lip Reanimation Outcomes Questionnaire results before and after surgery^a.

Domain	Pre-procedure, mean \pm SD	Post-procedure, mean \pm SD
Appearance	4.58 \pm 1.41	2.29 \pm 0.80
Oral competence	4.73 \pm 1.84	3.15 \pm 1.25
Speech	4.54 \pm 2.11	3.15 \pm 1.52
Overall	4.62 \pm 1.37	3.08 \pm 1.07

SD = standard deviation.

a) Pre- and post-procedure questionnaire results are shown for each domain. A lower post-procedure mean indicates improvement.

TABLE 2

Results of photographic evaluation at follow-up. The mean score^a for each type of smile is shown. In general, a fine symmetry is seen at rest and asymmetry worsens with increasing smile intensity.

Smile pose	Mean \pm SD
Rest	2.26 \pm 0.70
Mona Lisa	2.92 \pm 0.99
Canine	3.95 \pm 1.37
Full mouth	4.67 \pm 1.11
Overall	3.45 \pm 1.40

a) The mean scores shown are the average scores of all physician ratings.

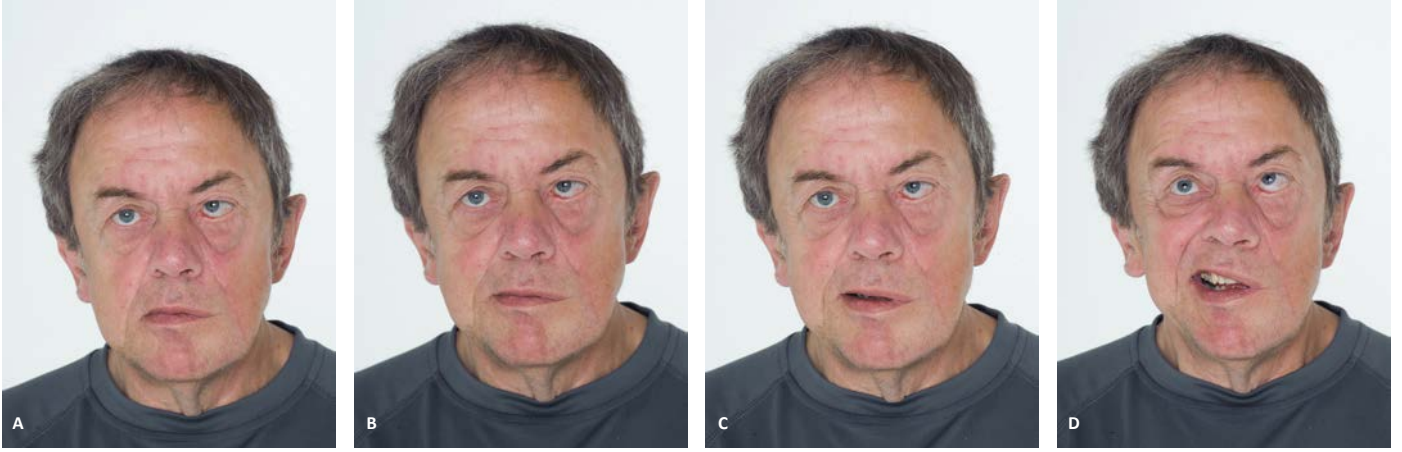speech. These aspects were evaluated using the LROQ and, on average, an improvement was seen in all domains. Our average follow-up was 46 months; and as such it is safe to assume that our technique does not lose its tensile strength over time, perhaps because of the double-layered approach. In this case series, only one patient required tightening of the suspension. We have had one patient who needed revision surgery ten years after suspension (same suspension technique but with a facelift incision) because of increased tightening that reduced mouth opening; and a small procedure was performed to loosen the suspension. Interestingly, when patients expressed their problems freely, they were all more interested in hearing more about possible further correction around the eyelids or eyebrows. This suggests that more focus should be put on the upper face of patients with facial paralysis.

One patient felt that her appearance and functional problems had become worse over time. Besides facial paralysis, this patient suffered from trigeminal trophic syndrome, which influenced her facial appearance in a severely detrimental way. She was not offered any revision surgery as the surgical result offered fine symmetry at rest, and her complaints were to some extent regarded as being based on her co-morbidity.

The absence of the palmaris longus tendon was 5%


 FIGURE 2

Post-operative photographs three months after surgery showing the four smile poses. Physician-rated symmetry for different smile poses: rest 3/3/3 (A), Mona Lisa smile 3/3/4 (B), canine smile 5/5/5 (C) and full mouth smile 6/6/6 (D). Patient self-rated symmetry on a 10-cm long visual analogue scale was at 1.5 cm suggesting a very poor self-rated symmetry.



in our study population, and this correlates well with previous findings where the absence of the tendon has been evaluated clinically [13]. The choice of autologous suspension material to use often boils down to either the palmaris longus tendon or fascia lata, and with our technique any of the two donor materials can be used. The latter has the advantages that it is always present, and a broader albeit much thinner graft can be harvested. The disadvantage is that donor site morbidity is worse than when the palmaris longus tendon is harvested. Muscle herniation is reported in about 20-30% of cases when harvesting a fascia lata graft [14, 15]. In this patient group, who are all either old and/or affected by significant co-morbidity, it is important not to create new problems for the patients while helping them with their facial paralysis. In our study, not a single complaint was found regarding the donor site in any of our patients. We therefore use the palmaris longus tendon as we have experienced no donor site morbidity, as it is thicker than the fascia lata graft and because it is very easily accessible.

There are several pitfalls in this series, including the retrospective approach, which introduces recall bias even though we used a validated questionnaire designed for retrospective use. Another weakness is the lack of systematic preoperative photographic documentation, which made it impossible to perform a systematic comparison of preoperative smile status with the status at long-term follow-up.

It should be emphasised that the treatment of choice will always be dynamic reconstruction, but for a select number of patients who are either not interested in a major procedure with a long rehabilitation process and for patients of old age and/or with severe co-mor-

bidity, static procedures still have a place in the management of these patients. Our procedure is easy and quick with minimal morbidity and provides a significant both cosmetic and functional improvement, which stands the test of time. The fact that five out of 19 patients died in the follow-up period also shows that for these patients, it was definitely the right choice to perform a static procedure that yields an immediate improvement in their quality of life.

CONCLUSION

We have presented our technique for passive suspension of the lip using the palmaris longus tendon. It is a technique that is easy to perform, has no significant complications, and it is a procedure that improves the patients' lives. It is an acceptable alternative for patients of old age or with severe co-morbidity when more advanced techniques are not indicated.

CORRESPONDENCE: Jens Ahm Sørensen, Plastikkirurgisk Afdeling Z, Odense Universitetshospital, Sønder Boulevard 29, 5000 Odense C, Denmark. E-mail: jens.sorensen@rsyd.dk

ACCEPTED: 8 January 2015

CONFLICTS OF INTEREST: Disclosure forms provided by the authors are available with the full text at www.danmedj.dk

LITERATURE

1. Coulson SE, O'Dwyer NJ, Adams RD et al. Expression of emotion and quality of life after facial nerve paralysis. *Otol Neurotol* 2004;25:1014-9.
2. Ryzenman JM, Pensak ML, Tew JM, Jr. Facial paralysis and surgical rehabilitation: a quality of life analysis in a cohort of 1,595 patients after acoustic neuroma surgery. *Otol Neurotol* 2005;26:516-21;discussion 521.
3. Liu YM, Sherris DA. Static procedures for the management of the midface and lower face. *Facial Plast Surg* 2008;24:211-5. Fisher E, Frodel JL. Facial suspension with acellular human dermal allograft. *Arch Facial Plast Surg* 1999;1:195-9.
4. Konior RJ. Facial paralysis reconstruction with Gore-Tex Soft-Tissue Patch. *Arch Otolaryngol Head Neck Surg* 1992;118:1188-94.
5. Alex JC, Nguyen DB. Multivector suture suspension: a minimally invasive technique for reanimation of the paralyzed face. *Arch Facial Plast Surg* 2004;6:197-201.
6. Rose EH. Autogenous fascia lata grafts: clinical applications in reanimation

- of the totally or partially paralyzed face. *Plast Reconstr Surg* 2005;116:20-32; discussion 25-33.
7. Alexander AJ, de Almeida JR, Shrime MG et al. Novel outpatient approach to lower lip reanimation using a palmaris longus tendon sling. *J Otolaryngol Head Neck Surg* 2011;40:481-8.
 8. Yoleri L, Gungor M, Usluer A et al. Tension adjusted multivectorial static suspension with plantaris tendon in facial paralysis. *J Craniofac Surg* 2013;24:896-9.
 9. Ibrahim AM, Rabie AN, Kim PS et al. Static treatment modalities in facial paralysis: a review. *J Reconstr Microsurg* 2013;29:223-32.
 10. de Almeida JR, Alexander AJ, Shrime MG et al. Development and preliminary validation of the lip reanimation outcomes questionnaire. *Otolaryngol Head Neck Surg* 2010;143:361-6.
 11. Weston GW, Poindexter BD, Sigal RK et al. Lifting lips: 28 years of experience using the direct excision approach to rejuvenating the aging mouth. *Aesthet Surg J* 2009;29:83-6.
 12. Troha F, Baibak GJ, Kelleher JC. Frequency of the palmaris longus tendon in North American Caucasians. *Ann Plast Surg* 1990;25:477-8.
 13. Bak K, Jorgensen U, Ekstrand J et al. Results of reconstruction of acute ruptures of the anterior cruciate ligament with an iliotibial band autograft. *Knee Surg Sports Traumatol Arthrosc* 1999;7:111-7.
 14. Chibber PJ, Shah HN, Jain P. A minimally invasive technique for harvesting autologous fascia lata for pubo-vaginal sling suspension. *Int Urol Nephrol* 2005;37:43-6.

Download Appendix 1 from www.danmedj.dk

Dan Med J 2015;62(3):A5019