

Favourable results of Mohs micrographic surgery for basal cell carcinoma

Robert Gniadecki¹, Martin Glud¹, Kia Mortensen¹, Bo Bang², Edyta Biskup¹ & Silje Haukali Omland¹

ABSTRACT

INTRODUCTION: Basal cell carcinoma (BCC) is the most common malignant neoplasm with an annual incidence approaching 200/100,000 person-years. Mohs micrographic surgery (MMS) is widely used in North America and in Europe for treatment of BCC. This technique ensures radical tumour removal, sparing of the surrounding healthy skin, and it also offers higher cure rates than standard tumour excision with a predefined margin of healthy skin. The superiority of MMS relies on the fact that the entire (100%) margin of the excised tissue is examined microscopically for residual tumour in contrast to the traditional histopathological examination, in which 2% of the margin is examined.

METHODS: In Denmark, MMS was first introduced by us in 2012. In the present study, we retrospectively included all patients who underwent MMS from May 2012 to June 2015.

RESULTS: A total of 231 patients with 263 BCC were included. The mean age was 66.1 years. The most common localisations were the forehead (31.3%), the nose (31.0%) and the cheek (14.7%). Primary BCC comprised 54.0%; the remaining cases were relapses, most frequently after curettage (36.9%), radiotherapy (18.9%) and photodynamic therapy (11.7%). MMS leads to 40% smaller skin defects than standard excisions with 4 or 6 mm margins. Closure of skin defects was achieved by side-to-side closure in 49% and by local flaps in 40%. There were no relapses during the observation time. The safety, cosmetic and functional outcome were excellent.

CONCLUSIONS: We recommend that MMS be included in the Danish BCC treatment guidelines, especially for high-risk BCC in the face, in line with standard practice in Europe and the United States.

FUNDING: none.

TRIAL REGISTRATION: not relevant.

Mohs surgery is a micrographic surgical technique in which skin tumours are excised in stages. The extent of surgery is guided by histological examination of the entire lateral and deep margins [1, 2]. Due to very high cure rates (> 95%) and sparing of the surrounding healthy skin, Mohs micrographic surgery (MMS) is particularly useful for treatment of basal cell carcinoma (BCC) in the face. MMS is well-established in North

America and in many European countries [3], but has only recently become available in Denmark. We introduced this technique in 2012, and we here describe the feasibility, treatment outcomes and safety of MMS.

METHODS

All patients with a histologically verified BCC who underwent MMS from May 2012 to June 2015 were included. We excluded one female patient with a recurrent BCC on the forehead who was referred to a plastic surgeon for resection and closure due to a very large subclinical lateral cancer invasion. Patient accrual is shown in **Figure 1**. We used the fresh tissue technique in which the tumour is excised with an approximate 2-mm margin of normal skin at a 45° incision angle [1] (**Figure 2**). The specimen was dye-marked and 12 consecutive 10-µm sections were obtained for staining with haematoxylin and eosin and with toluidine blue. To score the section as tumour-free, we required a minimum of two consecutive, good-quality sections without visible BCC cells. The diameters of the tumours and the defect after excisions were measured with a sterile paper ruler in two dimensions, d_1 and d_2 . The area (S) of the lesion was calculated by approximation to the elliptic shape: $S = 0.25 \times \pi \times d_1 \times d_2$.

Trial registration: not relevant.

RESULTS

Patients

We included 231 patients (111 men, 120 women) with 263 BCC (**Figure 1**). The mean age was 66.1 years (range: 23-95 years). The most common localisations were the forehead (31.3%) and the nose (31.0%), followed by the cheek (14.7% of tumours) (**Figure 3**). BCC was slightly more frequent on the right side of the face (40.3% versus 35.7% on the left side, and 24.0% in the midline). Primary BCC comprised 54.0%; the remainder of the cases were relapses, most frequently after curettage (36.9%), radiotherapy (18.9%), photodynamic therapy (11.7%) or multiple treatment modalities (16.2%). A total of 63 tumours were in the "low-risk zones" (cheek, $n = 37$; scalp, $n = 15$; neck, $n = 4$, trunk or extremities, $n = 7$). In all, 34 tumours had a diameter exceeding 20 mm in one of the axes (T2); 14 of these were primary tumours and 20

ORIGINAL ARTICLE

1) Department of Dermato-Venerology, Bispebjerg Hospital
2) LEO Pharma A/S, Denmark

Dan Med J
2015;62(12):A5171

FIGURE 1

Accrual of patients for Mohs micrographic surgery.

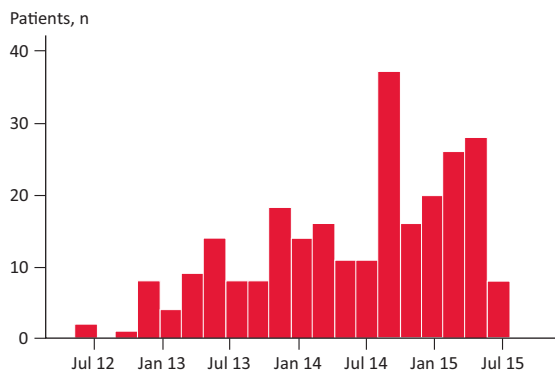
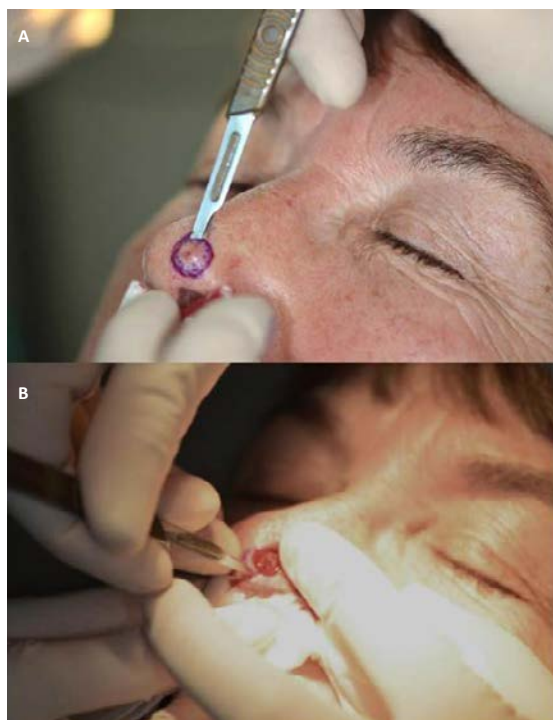


FIGURE 2

Mohs micrographic surgery technique for basal cell carcinoma: **A.** Tumour excised with narrow margins (1-2 mm) at a 45° incision angle. **B.** Second round excision of the residual tumour mapped to the marked area, based on histological examination.



were relapsing tumours. There was no difference in the anatomic localisation between primary and recurrent tumours.

Micrographic excision

Complete removal of BCC was achieved with one round of excision in 36.5% of cases; 45.2% required two rounds

of surgery, whereas three or more rounds were required in 12.5% and 5.8% of tumours, respectively. As expected, relapsing tumours required more rounds of surgery than primary tumours before histologically free margins were achieved. 90.2% of primary tumours could be eradicated with one or two rounds of surgery, whereas 28.6% of patients with relapsing tumours required 3-6 rounds (significant difference $p = 0.002$; chi-squared test). This reflects the asymmetric, clinically imperceptible growth of recurrent facial BCC. This difference was also reflected in the size of the final defects. Whereas the estimated size of recurrent tumours was only slightly larger than the size of primary tumours, 83.2 mm² (median) (range: 7.1-518.1) versus 70.7 mm² (range: 7.1-1,371.8), the final defect after Mohs procedure was significantly larger than after removal of the primary tumour (193.1 mm² (range: 12.6-1,884.0) versus 127.2 mm² (range: 7.1-1,695.6), $p = 0.0009$, Mann-Whitney test) (Figure 4).

MMS was tissue-sparing comparing with a standard excision with pre-determined margins. After Mohs procedure, the size of the final defect was 1.34-fold the size of the tumour (95% confidence interval (CI): 1.10-1.59). In comparison, an excision with a 4-mm margin (which is an accepted value for excision of primary BCC in Denmark) [4] will increase the size of the defects 3.0-fold (95% CI: 2.77-3.24, $p < 0.0001$, Mann-Whitney test). Thus, MMS reduced the final size of skin defect by 43% (95% CI: 38-47%) in primary tumours using a 4-mm excision margin as reference. In high-risk, recurrent tumours where a 6-mm excision margin should be employed, the final defect after MMS is reduced by 45% (95% CI: 35-54%) compared with conventional surgery.

Closure of skin defect

Most (49%) of the defects were closed by side-to-side closure after enlarging the circular defect to an elliptic (fusiform) shape, aided, if needed, by M-plasties to reduce the length of the scar. Local advancement of rotational flaps accounted for 26.2% of closures, whereas transposition flaps were used in 14.4% of cases. The remainder of the cases were repaired by a variety of other techniques including island flaps or full-thickness skin grafts or were left for second intention healing. The pattern of skin closures did not differ significantly between the primary and relapsing tumours, but depended on the localisation of the lesion (Figure 3). The cosmetic outcome was excellent; there were no cases of wound dehiscence, hypertrophic scarring or keloid. In six cases in which transposition flaps were used, the flap developed trap door deformity (swelling of the central portion of the flap), which is a well-known phenomenon. In five cases, the deformity resolved after intralesional injection of 10 mg/ml triamcinolone. One case with use of

the nasolabial transposition flap to the ala nasi, a surgical revision of the flap was performed.

Outcome and safety

None of the patients developed relapse after Mohs excision. However, the observation time was limited since only 117 tumours (44.8%) have been followed for one year or more after surgery (Figure 1).

One patient experienced a severe adverse event: After excision of an extensive BCC on the cheek repaired with a rotation flap, a large haematoma developed requiring hospitalisation and surgical intervention. Furthermore, seven minor adverse events were observed: four patients had superficial infection of the surgical wound requiring antibiotic therapy (in all cases after excision on the nose), three patients had minor haematomas, which resorbed spontaneously without any intervention, one patient developed ischaemia of the distal portion of the flap, and one patient had a partial necrosis of the full thickness transplant. The last-mentioned patient was treated conservatively with an excellent cosmetic and functional outcome. No patients experienced functional nerve damage.

DISCUSSION

MMS is an effective and safe treatment of facial BCC. MMS is the treatment of choice for high-risk tumours and recurrent BCC in several countries [5-7]. Unfortunately, MMS is underused in Scandinavia despite the high incidence of BCC and an increasing incidence of BCC in younger individuals. This study documents that Mohs surgery is a feasible and valuable treatment option for BCC in a dermatological setting in Denmark. Currently, our centre performs 5-7 Mohs procedures weekly, complying with international guidelines for volume requirements, and the centre is accredited by the European Society of Mohs Surgery. Patient profiles, surgical techniques and outcomes are comparable to those reported from other established Mohs surgery centres [8, 9].

Dermatologic surgeons performing excisions of BCC in the face are limited in their choice of closure techniques for skin defects. We have been particularly cautious regarding the use of asymmetric flaps, such as transposition, island and rotational flaps. These types of closures distort the geometry of the initial defect and make it very difficult to trace residual tumours in case of incomplete excision and relapse. MMS obviates this problem because microscopically free margins are ensured before closure. In the rare cases of tumour regrowth after MMS, relapses can be re-excised with MMS, which allows tracing of residual cancer independently of the depth of invasion and shape.

MMS also shows superiority for tumours in difficult locations of the face such as the eyelid, ala nasi or the

FIGURE 3

Distribution of facial basal cell carcinoma treated with Mohs micrographic surgery. Each red circle shows an individual tumour. The pie diagrams show frequencies of different types of wound closures in different anatomical areas of the face.

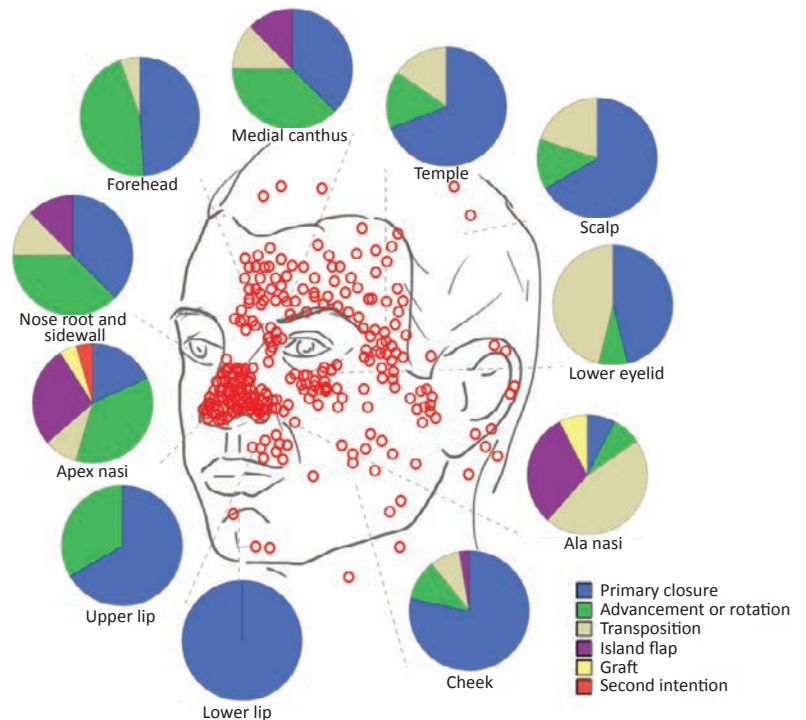
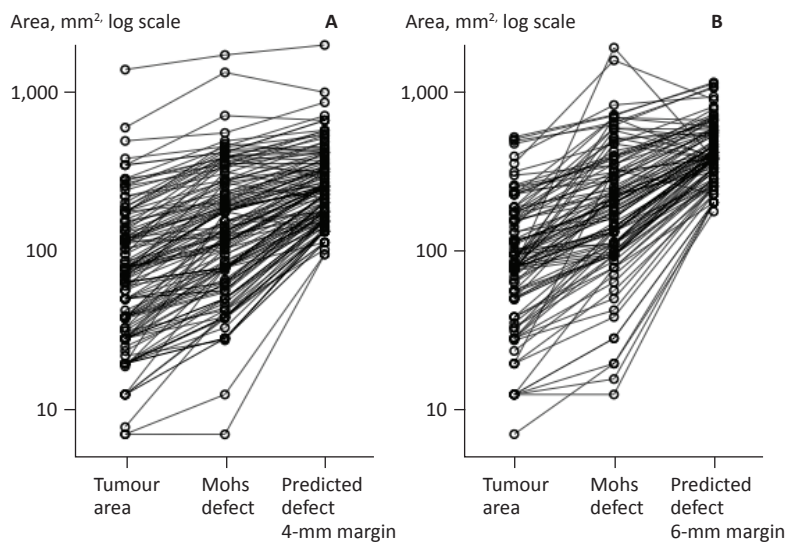


FIGURE 4

Relationship between the area of the tumour and the area of Moh's defect for primary facial basal cell carcinoma (A) and for the recurrent tumours (B). For comparative purposes we also show the predicted area of the surgical defect after excision with predetermined 4-mm margins (primary tumours) and 6-mm margins (recurrent, high-risk tumours).



ear, where closures of larger defects are technically challenging. In the past, narrowed excision margins for

these tumours were used involving a compromise between the size of the surgical defect and the achieved cure rate. With the advent of MMS, such compromises are no longer necessary since MMS ensures that only tumourous tissue is excised leaving the surrounding healthy skin intact. Our results show that the area of the excision can be reduced by > 40% by using the micrographic approach rather than excision with predetermined margins. This increases the chance of direct closure (side-to-side) of the scar and yields a better cosmetic and functional outcome.

The per-tumour cost of treatment with MMS is almost comparable to that of conventional surgery [5] and may prove more cost-effective in recurrent, high-risk tumours [5, 10]. Furthermore, the intraoperative histological evaluation reduces the use of standard histological examination in pathology departments and should be taken into account when considering the cost-effectiveness of MMS. As a safe, highly efficacious and tissue-sparing technique, MMS is an excellent alternative to radiotherapy and standard surgical excision and should be considered as first choice for high-risk facial BCC, in particular for recurrent tumours [11, 12].

CORRESPONDENCE: Robert Gniadecki. E-mail: r.gniadecki@gmail.com

ACCEPTED: 22 October 2015

CONFLICTS OF INTEREST: Disclosure forms provided by the authors are available with the full text of this article at www.danmedj.dk

LITERATURE

1. Benedetto PX, Pobleto-Lopez C. Mohs micrographic surgery technique. *Dermatol Clin* 2011;29:141-51.
2. Swanson NA. Mohs surgery. Technique, indications, applications, and the future. *Arch Dermatol* 1983;119:761-73.
3. Hauschild A, Breuninger H, Kaufmann R et al. Short German guidelines: basal cell carcinoma. *J Dtsch Dermatol Ges* 2008;6(Suppl 1):S2-S4.
4. Kimyai-Asadi A, Alam M, Goldberg LH et al. Efficacy of narrow-margin excision of well-demarcated primary facial basal cell carcinomas. *J Am Acad Dermatol* 2005;53:464-8.
5. Mosterd K, Krekels GAM, Nieman FH et al. Surgical excision versus Mohs micrographic surgery for primary and recurrent basal-cell carcinoma of the face: a prospective randomised controlled trial with 5-years' follow-up. *Lancet Oncol* 2008;9:1149-56.
6. Van Loo E, Mosterd K, Krekels GA et al. Surgical excision versus Mohs micrographic surgery for basal cell carcinoma of the face: A randomised clinical trial with 10 year follow-up. *Eur J Cancer* 2014;50:3011-20.
7. Kauvar AN, Cronin T Jr, Roenigk R et al. Consensus for nonmelanoma skin cancer treatment: basal cell carcinoma, including a cost analysis of treatment methods. *Dermatol Surg* 2015;41(5):550-71.
8. Paoli J, Daryoni S, Wennberg AM et al. 5-year recurrence rates of micrographic surgery for aggressive and recurrent facial basal cell carcinoma. *Acta Dermato-Venereol* 2011;91:689-93.
9. Leibovitch I, Huilgol SC, Selva D et al. Basal cell carcinoma treated with Mohs surgery in Australia I. Experience over 10 years. *J Am Acad Dermatol* 2005;53:445-51.
10. Tierney EP, Hanke CW. Cost effectiveness of Mohs micrographic surgery: review of the literature. *J Drugs Dermatol* 2009;8:914-22.
11. Thissen MR, Neumann MH, Schouten LJ. A systematic review of treatment modalities for primary basal cell carcinomas. *Arch Dermatol* 1999;135:1177-83.
12. Connolly SM, Baker DR, Coldiron BM et al. AAD/ACMS/ASDSA/ASMS 2012 appropriate use criteria for Mohs micrographic surgery: a report of the American Academy of Dermatology, American College of Mohs Surgery, American Society for Dermatological Surgery Association, and the American Society for Mohs Surgery. *J Am Acad Dermatol* 2012;67:531-50.