

Endoscopic treatment of colorectal perforations – a systematic review

Mohamed Ali Hassan, Christian Øystein Thomsen & Peter Vilmann

ABSTRACT

INTRODUCTION: Iatrogenic colon perforation is a feared complication to colonoscopy. Optimal management of the complication remains controversial. Traditionally, patients have been referred to surgery. Now, with technological advances, endoscopic closure is increasingly performed as minimally invasive therapy. The aim of this systematic review was to assess the existing evidence in this field.

METHODS: Literature was searched on PubMed, Embase and the Cochrane databases. Papers found were reported according to the PRISMA guidelines. Trials on animals were excluded.

RESULTS: A total of 32 articles were assessed, including 19 case reports, one case control, three prospective studies and nine retrospective studies. The total number of patients who have undergone endoscopic closure (apart from case reports) and reported in the literature is 203 patients. Studies have reported a clinical success rate of 87.8% (standard deviation: $\pm 13.0\%$) on average and a median of 92.3% (range: 58.6-100). The total number of patients needing surgery after attempted clip closure was 30 (14.7%); another four were found to have sealed perforations during surgery. One patient died after clip failure (0.5%). Articles presented a favourable, high outcome for endoscopic closure of iatrogenic colorectal perforations.

CONCLUSION: In a highly selective group of patients, endoscopic closure of iatrogenic colon perforations is recommended if the expertise is available.

In the context of a growing elderly population worldwide that calls for medical attention, the implementation of national screening programmes for colorectal cancer and the development of advanced endoscopic therapeutic procedures have evolved. In line herewith, the number of sigmoidoscopy/colonoscopies has increased significantly. Iatrogenic perforation is a feared complication, and approaches involving endoscopic management are of increasing interest.

Perforations during colonoscopies are rare, and complication rates vary between centres and with study designs (**Table 1**). It seems that the perforation rate has decreased during past years for diagnostic (from 0.03-0.8% to 0.07%) and therapeutic colonoscopy (from 0.15-3% to 0.1%) [1-3].

Perforations may occur due to excessive mechanical force, either if the endoscope is directly inserted into a diverticulum or when passing a difficult bend as well as by retro-flexion in the rectum. Over-insufflation can cause barotrauma, and thermal injury caused by the use of electrocoagulation or argon plasma coagulation can lead to transmural burn and tissue necrosis [1, 4-6].

The most common site for perforations is the recto-sigmoid junction or the sigmoid colon. Risk factors include diverticulosis, severe inflammation, cancer and stenosis. Other risk factors are therapeutic interventions like endoscopic mucosal resection and endoscopic submucosal dissection, as well as size and number of polyps removed during intervention. The caecum with its thinner wall and larger diameter is more susceptible to thermal injuries and barotrauma. Defects seen during diagnostic procedures have been reported to be larger than those produced during therapeutic interventions [1, 4-7].

Perforations are detected either immediately during sigmoidoscopy/colonoscopy by visualisation of extraintestinal tissue or post-procedure by visualisation of free air on abdominal computed tomography. The clinical signs are abdominal pain, distension, tachycardia, fever and nausea. The laboratory findings include leukocytosis and/or elevated C-reactive protein [8].

Treatment has traditionally been surgery either by open or laparoscopic suturing of the perforations. However, when perforations are not manageable by suturing, more extensive surgery with bowel resection and stoma may be required. Conservative non-surgical management has been described in small series based on highly selected patient groups [5, 9-11].

Endoscopic closure of perforations of the colon has previously been reported only sporadically in the literature since the first case report by Yoshikane et al in 1998 [12]. Subsequently, it has been reported that different types of endoscopic closure devices have been used to close perforations, most commonly endoscopic clips [4, 13].

The aim of this article was to assess the existing evidence on endoscopic closure of iatrogenic perforations of the colon and rectum through a systematic review of the literature.

SYSTEMATIC REVIEW

Department of Surgery,
Herlev Hospital,
Denmark

Dan Med J
2016;63(4):A5220

 TABLE 1

Incidence of perforations based on endoscopy performed in 1990-2007, studies published in 2000-2008 [1].

Procedure	Studies, n	Procedures, n	Incidence, %
Overall diagnostic colonoscopy	15	491,311	0.07
Therapeutic colonoscopy	15	74,630	0.1
Overall sigmoidoscopy	4	109,614	0.04
Polypectomies	4	31,516	0.5
EMR	17	1,858	0.2
ESD	7	648	5

EMR = endoscopic mucosal resection; ESD = endoscopic submucosal dissection.

METHODS

The literature search was performed by two authors (MAH, CØT). The strategy implemented was in accordance with the PRISMA guidelines.

Eligibility criteria and information sources

We searched the databases for clinical trials, case reports and small series and for retrospective, prospective and cohort studies. Studies published in English were included. Trials on animal models were excluded. Data were gathered through literature search in the following databases: MEDLINE, Embase and the Cochrane library. No limitations were used.

The search was made until 27 February 2015. The search criteria used were (“colonoscopy/adverse effects”[MeSH Terms]) AND clip, OR (((“colonoscopy/adverse effects”[MeSH Terms]) AND perforation)) AND clip, OR (“colon”[MeSH Terms]) AND perforation AND clip, OR ((clip) AND closure) AND colon, OR ((rectum) AND clip) AND perforation. Additionally, records were added after the authors’ reference lists had been reviewed manually for relevant articles. In case an article could not be retrieved, the author or publisher was contacted.



KEY POINTS

The most common site for perforation is the recto-sigmoid junction or the sigmoid colon.

Defects seen during diagnostic procedures have been reported to be larger than those caused by therapeutic interventions.

The treatment of perforations has traditionally been surgery, i.e. either open or laparoscopic sewing of the perforation.

Several different endoscopic clips are available on the market. The Over-The Scope-Clip provides more strength and better tissue capture compared to traditional clips.

Aspects taken into account before an attempted closure was bowel preparation, faecal leakage, size of the lesion, technical feasibility and the expertise available.

Study selection and data collection process

The search identified 275 records (Figure 1) including the manual reference list search. A total of 67 records were screened and 32 records were excluded. This included trials on animals, non-English language publications, perforations in the upper gastrointestinal (GI) tract, closure of fistulas or duplicates. A total of 35 full-text articles were retrieved for closer evaluation. Three of these were excluded due to conflicts of interest, other causes of perforation than sigmoidoscopy/colonoscopy or a combination of surgery and clipping. Thus, a total of 32 articles were finally included in the qualitative analysis of this review.

RESULTS

This review included 19 case reports and 13 studies, including three prospective studies, one case control study and nine retrospective studies.

Case reports

A total of 19 case reports [12, 14-31] with reports on 23 patients were included. Cases were published during the 1997-2015 period (Table 2). Perforations were associated with both diagnostic and therapeutic sigmoidoscopies/colonoscopies. Successful endoscopic closure was reported in all but one case [20].

Case-control studies

Won et al [32] included 22 patients between 2004 and 2009 in a single-centre case-control study. Patients were divided into a surgical and non-surgical group. The non-surgical group (two diagnostic- and three therapeutic colonoscopies) underwent conservative treatment with successful clip application and closure of the perforations. A total of 17 patients (nine diagnostic and eight therapeutic colonoscopies) were treated surgically. The authors found a significant difference in favour of the non-surgical group regarding fever and abdominal pain, but no significant difference in length of stay (LoS) between the two groups. Sample size is small in this study and procedures are not standardised; furthermore, pain is a subjective symptom.

Prospective studies

Voermans et al [33] included 36 patients (13 colon- and 23 upper-GI tract) with acute iatrogenic perforations of the GI tract from 2009 to 2010 in a multicentre study. The clip device used was the Over-The Scope-Clip (OTSC) (Ovesco Endoscopy, Tubingen Germany). Endoscopic repair was conducted according to a standardised operating procedure. Perforations of 3 cm or less were included. The primary endpoints were successful closure, absence of leakage on water-soluble contrast X-ray and absence of adverse events within 30 days after endo-

scopic closure. Out of 13 colon perforations, 12 were managed endoscopically (92% success rate). However, one patient died after 36 h of inclusion after abdominal surgery due to failure to close the perforation with clips.

Gubler et al [34] included 14 GI perforations, (nine colon- and five upper GI tract) to endoscopic closure between 2009 and 2011 in a single-centre study. The main outcome was defined as technically successful closure after subsequent clinical observation for 24 h. All nine colon perforations were closed endoscopically with a single OTSC. The authors reported a technical success rate of 100%. Three patients underwent laparoscopy due to pain where the lesion was confirmed to have been sealed.

Heldwein et al [35] included 2,257 patients and found 26 perforations in a multi-centre study with data collected in the course of 20 months. The endpoints were bleeding, bowel perforation and death during a 30-day follow-up period. Of the 26 perforations observed, nine were detected immediately, 11 within 24 h and six after more than 24 h. A total of 12 perforations were managed successfully non-surgically; five by clip application and seven conservatively.

Retrospective studies

Magdeburg et al [36] included 22,924 colonoscopies and detected 105 iatrogenic perforations (29 diagnostic and 76 therapeutic perforations) in the 2004-2011 period in a single-centre study. A total of 71 patients underwent immediate endoscopic repair with clips, and 59 of these were successful (83.1%). Clip application was possible in 62 of 76 (81.55%) cases in the therapeutic group, whereas clip application was possible only in nine of 29 (31.03%) patients in the diagnostic group. This is the largest study conducted to date. The definition of a successful closure was not detailed.

Kim et al [37] included 115,285 diagnostic sigmoidoscopies/colonoscopies and observed 26 perforations, from 2000 to 2011 in a multicentre study. Endoscopic closure was attempted in 16 patients, 13 were successful (81%). Successful closure was defined as complete closure of mucosal defect and improvement of clinical manifestations such as fever, leukocytosis and signs of peritoneal irritations. Perforations were significantly smaller in the endoscopic closure group. None of the patients in the endoscopic clipping group needed further surgical treatment.

Cho et al [38] investigated 51,738 diagnostic and therapeutic colonoscopies with 33 iatrogenic perforations detected between 2005 and 2009 at three centres. A total of 29 perforations were initially managed by endoscopic closure, with success in 17 patients (59%) defined as a hospital stay that was shorter than two weeks, no complications and complete resolution of the

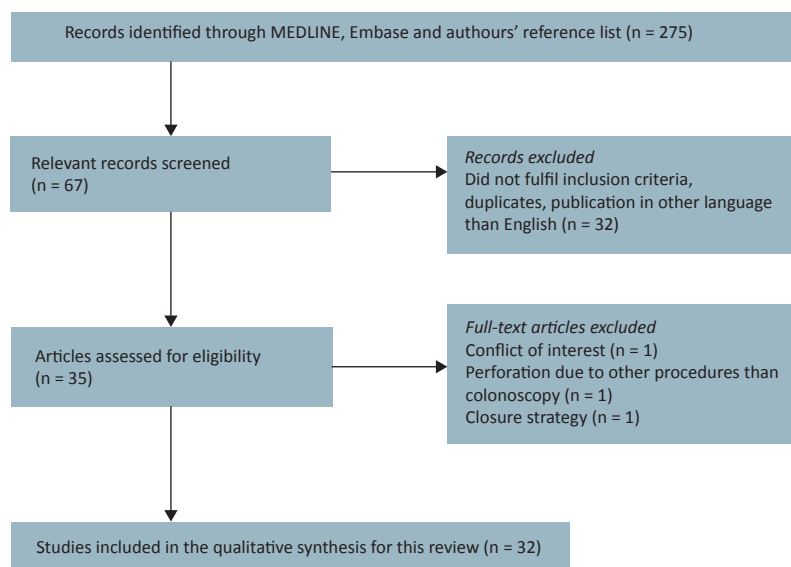
perforations. Complications, defined as a longer hospital stay than two weeks, were seen in five patients, including two with abscess formation. A total of 22 patients were treated non-surgically (76%). Seven patients underwent surgery.

In a study by Jovanovic et al [39], 8,601 colonoscopies were performed. Twelve iatrogenic perforations occurred (five diagnostic and seven therapeutic colonoscopies). Data were collected from a single centre between 2002 and 2008. Endoscopic closure was attempted in six patients of whom one failed (success rate 83%). The remaining six did not undergo an endoscopic attempt of closure due to the size of the perforations, technical difficulties, stool contamination or lack of experience.

Kang et al [40] included 20,660 sigmoidoscopies and 17,102 colonoscopies. Data on 53 procedure-related perforations from 2000 to 2007 were evaluated in a single-centre study. A total of 19 patients were treated conservatively and 34 underwent surgery. Conservative treatment was described as all means of non-operative medical management including fasting, hydration, intravenous antibiotics and serial abdominal examinations. The conservative group included seven successful endoscopic closures and 12 close observations. Endoscopic clipping was successful in seven out of nine attempted closures (78%). The remaining two underwent surgery. Analysing the conservative group, authors found that patients treated by clipping had significantly fewer days of fasting, a more limited use intravenous antibiotics

 FIGURE 1

Search strategy flow diagram.



and a shorter LoS than the patients in the non-clipping group.

Taku et al [41] presented 15,160 therapeutic colonoscopies with 23 colon perforations. Data were collected from the 1999-2003 period at four centres. Out of the 23 cases, 16 patients had immediate perforations, and the remaining seven had delayed perforations. Endoscopic clipping was attempted in 13 patients (56.5%) with immediate perforations. Successful closure was possible in nine patients (69.2%). The remaining patients in this group were managed surgically (five patients) and conservatively (two patients). In the group with delayed perforations, one was managed surgically and six conservatively. Successful closure was defined as clipping without any untreated closure or closure defects.

Yang et al [42] included 118,115 colonoscopies resulting in 38 perforations; 13 diagnostic and 25 therapeutic. Data were collected from 2001 to 2008 at a single centre. Perforations were categorised as endoscopically evident, suspected or radiologically proven. Successful closure was defined as a complete closure of the definite or suspected mural defect. Endoscopic closure after diagnostic perforations was attempted in six

out of 13 perforations (42.6%), with successful outcome without surgery in five of six patients (83.3%); the last patient underwent surgery without further complications. In all, attempted closure was successful in 21 of 22 patients (95.5%). Perforations were smaller in the therapeutic than in the diagnostic group (Table 3).

Niyashama et al [43] had only two patients with perforations in the sigmoid colon after therapeutic colonoscopy and both were managed successfully with clips.

Seebach et al [44] presented a small study that included three cases with a colon perforation out of seven GI perforations. Three patients were treated successfully by a single OTSC. One of these patients underwent emergency laparotomy. Free air and a closed perforation were found. The further course was uneventful for all patients.

The total number of patients (apart from case reports) who have undergone endoscopic closure and been described in the literature in this study is 203. The size of perforation ranged from 2.9 to 40 mm and size was reported in seven out of 13 studies (Table 3). The mean clinical success was 87.8% (standard deviation:

TABLE 2

Summary and results of case reports.

Reference	Patients, n	Size of perforation, mm	Location	Closure device	Comment
Albuquerque et al, 2008 [23]	1	20	Sigmoid colon	Clip: type not described	–
Ahlawat et al, 2008 [26]	1	15	Rectum	Clip: type not described	–
Barbagallo et al, 2007 [22]	1	20	Sigmoid colon	Clip: Endoclip, Olympus Co., Japan	–
Celestino et al, 2006 [18]	1	15	Transverse colon	Endo loop: type not described	Initial fail with clip application
Coumaros et al, 2010 [27]	1	10	Recto-sigmoideum	Clip: QuickClip, Olympus Co., Japan Clip: Resolution Clip, Boston Scientific, USA	–
Coriat et al, 2011 [28]	1	15	Rectum	Clip: Over-The Scope-Clip, Ovesco Endoscopy GmbH, Germany	–
Donatelli et al, 2014 [24]	1	7	Descending colon	Clip: Over-The Scope-Clip, Ovesco Endoscopy GmbH, Germany	–
Han et al, 2011 [19]	2	–	1: descending colon 2: sigmoid colon	Band ligator: single-band ligator MD-48709, Akita Sumitomo Bakelite Co., Japan	Initial fail by clip application
Katsinelos et al, 2014 [17]	1	30	Rectum	Endo loop: MAJ-254, Olympus Co., Japan Clip: HX-600-900, Olympus Co., Japan	–
Ladas et al, 2014 [29]	1	10	Sigmoid colon	Clip: HX-201UR-135, Olympus Co., Japan	–
Lee et al, 2012 [30]	1	15	Rectum	Clip: type not described	–
Rodriguez Lopez et al, 2013 [15]	1	–	Sigmoid colon	Clip: Over-The Scope-Clip, Ovesco Endoscopy GmbH, Germany	Failure
Mana et al, 2001 [20]	1	–	Sigmoid colon	Clip: standard 6 mm itx-600-135, Omnilobo, Belgium	–
Diez-Redondo et al, 2012 [16]	1	12	Sigmoid colon	Clip: Over-The Scope-Clip, Ovesco Endoscopy GmbH, Germany Clip: Boston Scientific, USA	–
Sashiyama et al, 2011 [31]	1	25	Rectum	Clip: type not described	–
Sileri et al, 2009 [21]	1	30	Rectum	Clip: type not described	–
Trecca et al, 2008 [14]	3	1: 30 × 10 2: 12 3: 35 × 10	1: recto-sigmoideum 2: sigmoid colon 3: descending colon	Clip: TriClip, Cook Endoscopy, USA	–
Velchuru et al, 2013 [25]	1	30	Hepatic flexure	Clip: Resolution Clip, Boston Scientific, USA	–
Yoshikane et al, 1997 [12]	1	4	Descending colon	Clip: HX-5QR-1, Olympus Co., Japan	–

± 13.0) with a median of 92.3% (58.6-100). The total number of patients needing surgery as a consequence of clip failure was 30 (14.8%). In two additional articles, four patients underwent surgery and sealed perforation was confirmed [34, 44]. One patient died after reported clip failure (0.5%) [33].

DISCUSSION

In this systematic review, we searched the current literature on endoscopic management of iatrogenic colon perforations.

Traditionally, iatrogenic colon perforations have been treated surgically either by laparotomy or laparoscopy, but during the past decade, endoscopic alternatives have developed rapidly; and today an increasing number of perforations may be handled by flexible endoscopy with clips or loops. Conservative non-surgical management supplemented with antibiotics has been described in several small series based on highly selected patient groups [5, 10, 11].

Various endoscopic clips are available on the market. Traditional clips provide an adequate positioning of



TABLE 3

Summary of 13 prospective-, retrospective- and case control studies.

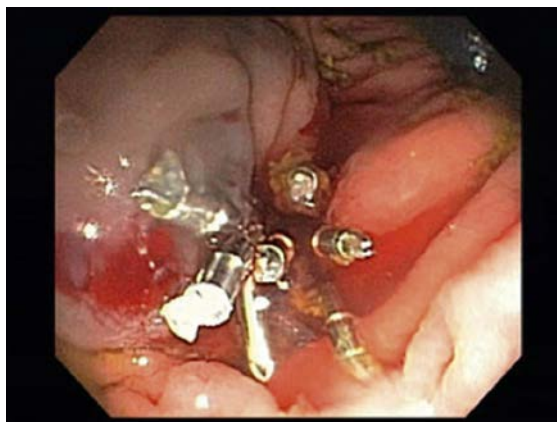Reference	Pa-tients, n	Perfor-ations, n	Attempted closure, n	Size of perfor-ation, range (mean), mm	Diagnos-tic/thera-peutic, n	Successful outcome after attempted closure, n/N (%)	Length of stay, mean (range), days	Clipping time, mean (range), min.	Applied clips, mean (range), n	Closure device
<i>Prospective</i>										
Gubbler & Bauerfind, 2012 [34]	9	9	9	6-30	2/7	9/9 (100)	5.67 (2-11)	10- 15	1	Clip: Over-The Scope-Clip, Ovesco Endoscopy GmbH, Germany
Voermans et al, 2012 [33]	13	13	13	< 30	5/8	12/13 (92.3) ^a	–	5.73 (1.48- 9.98)	–	Clip: Over-The Scope-Clip, Ovesco Endoscopy GmbH, Germany
Heldwein et al, 2005 [35]	2,257	26	5	–	-/5	5/5 (100)	–	–	–	–
<i>Case control</i>										
Won et al, 2012 [32]	22	22	5	–	3/2	5/5 (100)	8.2 (4.3-12.1)	–	–	–
<i>Retrospective</i>										
Cho et al, 2012 [38]	51,738	32	29	–	13/19	17/29 (58.6)	28.3 (13.9-42.7)	–	7.4 (3.9-10.9)	–
Kang et al, 2008 [40]	37,762	53	9	–	26/27	7/9 (77.8)	4.5 (1-9)	8.6	4.8 (1-15)	Clip: HX-610-135, HX-610-090L; Olympus Co., Japan
Kim et al, 2013 [37]	115,285	27	16	3-16 (10)	16/-	13/16 (81.2)	9 (5-18)	–	5.6 (1-18)	–
Jovanovic et al, 2011 [39]	8,601	12	6	4-20 (6.8)	5/7	5/6 (83.3)	–	–	5 (3-7)	Clip: EZ clip: HX-610-090; EX clip: HX-610-090L, Olympus Co., Japan
Magdeburg et al, 2013 [36]	22,924	105	71	–	29/76	59/71 (83.1)	4.08	–	–	Clip: Over-The Scope-Clip, Ovesco Endoscopy GmbH, Germany; clip: 1-6 Resolution Clip, Boston Scientific, USA
Niyashama et al, 2013 [43]	2	2	2	35-40 (37.5)	-/2	2/2 (100)	8	1: 7 2: 16	1: 1 2: 3	Clip Over-The Scope-Clip, Ovesco Endoscopy GmbH, Germany
Seebach et al, 2010 [44]	3	3	3	–	1/2	3/3 (100)	–	–	1	Clip: Over-The Scope-Clip, Ovesco Endoscopy GmbH, Germany
Taku et al, 2007 [41]	15,160	23	13	< 10	-/23	9/13 (69.2)	9.1 ^b (3-18)	–	–	Clip: HX-600-090L, Olympus Co., Japan
Yang et al, 2010 [42]	118,115	38	29	2.9-32 ^c	13/25	21/22 (95.5)	–	–	–	Clip: HX-6UR-1, HX-600-090L, Olympus Co., Japan

a) 1 patient died after clip failure.

b) Mean length of stay for 17 non-operated patients.

c) Mean size of respective diagnostic- and therapeutic perforations: 19.3 (6.5-32.1) mm and 5.8 (2.9-8.7) mm.

Successful closure of a rectum perforation with endoscopic clips.



the mucosa and submucosa, but they rarely obtain grip on deep layers of the gut such as the muscularis propria and serosa due to their relatively superficial effect. The OTSC consists of a transparent hood on which a strong metal clip is mounted. By suction of the tissue inside the hood, and assisted by a twin grasper, the clip is released [4, 13]. Gubler et al [34] and Voermans et al [33] advocate the use of OTSC for larger perforations owing to its better tissue grip and apposition of the sub mucosal layers. This latter point is of importance as evaluation of a complete clip closure can be difficult at the site. Cho et al [38] discussed the matter after having three cases where insufficient clip closure caused delayed and a need for more aggressive surgery. Based on the literature, the European Society of Gastrointestinal Endoscopy (ESGE) recommends use of the OTSC for larger perforations and the TriClip for smaller perforations [45].

Endo loops have also been used to close perforations. The perforation edges are brought together by clip application before the suction cap is put gently towards the lesion. Tissue is then aspirated before an endo loop is released onto the base [13, 17]. Endoscopic suture devices and staplers have been described in animal studies, but staplers are no longer promoted due to technical difficulties [4, 13].

We found a total of 19 case reports, 18 of which reported successful endoscopic closure (Table 2). In its nature the study design has weaknesses, e.g. publication bias and lack of a control population. However, it has been shown that endoscopic closure is technically possible.

Furthermore, 13 studies were found; three prospective studies, one case-control study and nine retrospective reviews (Table 3). Endoscopic closure was attempted immediately after detection of the perforation (diagnosed by direct visualisation or detection of free air on computed tomography/X-ray), in one study up to 3 h later [40]. Successful closure was defined inconsistently across the studies. Endoscopic treatment was attempted

if the endoscopist assessed that the perforation was suitable for clip closure. Aspects taken into considerations were bowel preparation, faecal leakage, technical feasibility and the endoscopist's experience. The size of the defects was described inconsistently; in seven out of 13 studies (range: 3-40 mm) [33, 34, 37, 39, 41, 42, 43]. Only four papers [33, 34, 41, 43] presented data on the mean and range of the perforations (Table 3). Various clip devices were used for closure (Table 2 and Table 3). Patients were monitored closely, fasted and treated with intravenous antibiotics after closure of the perforation.

Clip closure was reported for 203 patients with a success rate of 58.6-100% in a total of 13 studies. After clip failure, 34 patients were referred to surgery. Studies with a 100% success rate had very few patients (Table 3). The technical success closing perforations was higher in therapeutic than in diagnostic perforations. Magdeburg et al [28] reported an initial technical success of 81.55% for therapeutic perforations and 31.03% for diagnostic perforations. Three studies included only therapeutic perforations (20 patients) with a success rate of 69.2-100% [35, 41, 42]. One study excluded therapeutic lesions and investigated only diagnostic perforations with an 81% success rate [37]. Time spent closing perforations was approximately 5-15 min. A significantly shorter hospital stay was observed for endoscopy than for surgery, with the exception of three out of seven studies [32, 37, 38] (Table 3).

As perforation of the colon during sigmoidoscopy/ colonoscopy is a rare adverse event, a considerable number of patients is required to obtain eligible data. In the retrospective studies, possible recall bias and loss of data are known weaknesses; selection bias, and lack of standardisation are others. In contrast hereto, the large number of patients included speak in favour of these studies. The prospective studies included very few patients and represented a heterogeneous study group with perforations throughout the entire GI tract. Data should therefore be interpreted with caution. Technical details on closure procedure and terms that excluded patients were well documented in the prospective studies and to a lesser extent in the retrospective studies. There is good evidence in favour of a successful outcome after immediate endoscopic closure of iatrogenic colon perforation allowing for a reduction in the frequency of surgery. However, no randomised comparative controlled trials have been made comparing the gold standard of surgery with endoscopic closure. Due to ethical considerations related, e.g., to potential adverse events in case of clip failure or surgery when not required, a randomised controlled trial is not likely to be conducted in the near future. Nevertheless, future well-designed prospective studies are warranted to further document that endoscopic clip closure rather than refer-

ral to surgery should be attempted in selected patients if the expertise is available. This recommendation is in line with recent recommendations from the ESGE [45]. As endoscopic closure of colon perforations is likely to gain a stronger footing and to undergo further development, it should form part of future endoscopic training programmes.

Based on this review, we recommend that endoscopic closure of iatrogenic colorectal perforations smaller than 20 mm without faecal contamination be performed immediately when detected during colonoscopy. The procedure should be performed by an experienced endoscopist and careful post-therapeutic monitoring of the patient is required. Due to the rarity of the event, experience should guide the endoscopist on the preferred method of closure. Free intra-abdominal air in itself is not an indication for surgical exploration, but worsened clinical condition of the patient including development of a peritoneal reaction should immediately result in laparoscopic inspection of the closure. The preferred endoscopic clips are OTSC and TriClip, but it is expected that new types of clip will be developed.

CORRESPONDENCE: Mohamed Ali Hassan. E-mail: mohha08@gmail.com

ACCEPTED: 15 February 2016

CONFLICTS OF INTEREST: Disclosure forms provided by the authors are available with the full text of this article at www.danmedj.dk

LITERATURE

- Pantheris V, Haringsma J, Kuipers E et al. Colonoscopy perforation rate, mechanisms and outcome: from diagnostic to therapeutic colonoscopy. *Endoscopy* 2009;41:941-51.
- Broeders E, Al-Taher M, Poeters K et al. Verres needle desufflation as an effective treatment option for colonic perforation after colonoscopy. *Surg Laparosc Endosc Tech* 2015;25:e61-e64.
- Saito Y, Fukuzawa M, Matsuda T et al. Clinical outcome of endoscopic submucosal dissection versus endoscopic mucosal resection of large colorectal tumors as determined by curative resection. *Surg Endosc* 2010;24:343-52.
- Raju G, Saito Y, Matsuda T et al. Endoscopic management of colonoscopic perforations (with videos). *Gastrointest Endosc* 2011;74:1380-8.
- Iqbal C, Chun Y, Farley D et al. Colonoscopic perforations: a retrospective review. *J Gastrointest Surg* 2005;9:1229-36.
- Andersen ML, Pasha TM, Leighton JA et al. Endoscopic perforation of the colon: lessons from a 10-year study. *Am J Gastroenterol* 2000;95:3418-22.
- Lohsiriwat V. Colonoscopic perforation: incidence, risk factors, management and outcome. *World J Gastroenterol* 2010;16:425-30.
- Avgerinos DV, Laguna OH, Lo AY et al. Evolving management of colonoscopic perforations. *J Gastrointest Surg* 2008;12:1783-9.
- Coimbra C, Bouffioux L, Kohnen L et al. Laparoscopic repair of colonoscopic perforation: a new standard? *Surg Endosc* 2011;25:1514-7.
- Orsoni P, Berdah S, Verrier C et al. Colonic perforation due to colonoscopy: a retrospective study of 48 cases. *Endoscopy* 1997;29:160-4.
- Teoh AY, Poon CM, Lee JF et al. Outcome and predictors of mortality and stoma formation in surgical management of colonoscopic perforations: a multicenter review. *Arc Surg* 2009;144:9-13.
- Yoshikane H, Hidano H, Sakakibara A et al. Endoscopic repair by clipping of iatrogenic perforation. *Gastrointest Endosc* 1997;46:464-6.
- Al Ghossaini N, Lucidarme D, Bulois P et al. Endoscopic treatment of iatrogenic gastrointestinal perforations: an overview. *Dig Liver Dis* 2014; 46:195-203.
- Trecca A, Gaj F, Gagliardi G et al. Our experience with endoscopic repair of large colonoscopic perforations and review of the literature. *Tech Coloproctol* 2008;12:315-21.
- Rodriguez Lopez M, Blanco JJ, Martinez R et al. Clipping for endoscopic perforations: initial success but late complication requiring surgery. *Surg Endosc* 2013;27:3948-50.
- Diez-Redondo P, Blanco JJ, Lorenzo-Pelayo S et al. A novel system for endoscopic closure of iatrogenic colon perforations using the Ovesco clip and omental patch. *Rev Esp Enferm Dig* 2012;104:550-2.
- Katsinelos P, Lazaraki G, Chatzimavroudis G et al. Closure of an iatrogenic rectal perforation with the endoloop/clips technique in a purse-string fashion. *Ann Gastroenterol* 2014;27:264.
- Celestino C, Harz C, Decaestecker J et al. Endoscopic treatment of an iatrogenic perforation of the colon by using endoloop. *Gastrointest Endosc* 2006;64:653-4.
- Han JH, Park S, Youn S et al. Endoscopic closure of colon perforation with band ligation; salvage technique after endoclip failure. *Clin Gastroenterol Hepatol* 2011;9:54-5.
- Mana F, De Vogelaere K, Urban D et al. Iatrogenic perforation of the colon during diagnostic colonoscopy: endoscopic treatment with clips. *Gastrointest Endosc* 2001;54:258-9.
- Sileri P, Del Vecchio Blanco G, Benavoli D et al. Iatrogenic rectal perforation during operative colonoscopy: closure with endoluminal clips. *JLS* 2009; 13:69-72.
- Barbagallo F, Castello F, Saverio L et al. Successful endoscopic repair of an unusual colonic perforation following polypectomy using an endoclip device. *World J Gastroenterol* 2007;13:2889-91.
- Albuquerque W, Moreira E, Arantes V et al. Endoscopic repair of a large colonoscopic perforation with clips. *Surg Endosc* 2008;22:2072-4.
- Donatelli G, Vergeau BM, Dumont JL et al. Delayed successful treatment of iatrogenic colon perforation using an Over-The-Scope-Clip. *Endoscopy* 2014;46:285-6.
- Velchuru VR, Zawadzki M, Levin AL et al. Endoclip closure of a large colonic perforation following colonoscopic leiomyoma excision. *JLS* 2013;17: 152-5.
- Ahlawat SK, Charabaty A, Benjamin S et al. Rectal perforation caused by retroflexion maneuver during colonoscopy: closure with endoscopic clips. *Gastrointest Endosc* 2008;67:771-3.
- Coumaros D, Tselmeli N. Retroflexion-assisted EMR in the colon with immediate closure of a procedure-related perforation. *Gastrointest Endosc* 2010;72:1332-3.
- Coriat R, Leblanc S, Pommaret E et al. Endoscopic management of endoscopic submucosal dissection perforations: a new Over-The-Scope-Clip device. *Gastrointest Endosc* 2011;73:1067-9.
- Ladas SD, Kamberoglou D, Vlachogiannokos J et al. Combined use of metallic endoclips and endoloops using a single-channel scope in closing iatrogenic perforations and fistulas: two case reports and a literature review. *Eur J Gastroenterol Hepatol* 2014;26:119-22.
- Lee SH, Cheong YS. Successful endoscopic repair of an iatrogenic colonic perforation during diagnostic colonoscopy. *J Am Board Fam Med* 2012;25: 383-9.
- Sashiyama H, Fu KI, Hamahata Y et al. Closure of a rectal perforation by clipping the margins to presacral tissue. *Endoscopy* 2011;43.
- Won DY, Lee IK, Lee YK et al. The indications for nonsurgical management in patients with colorectal perforation after colonoscopy. *Am Surg* 2012; 78:550-4.
- Voermans RP, Le Moine O, von Renteln D et al. Efficacy of endoscopic closure of acute perforations of the gastrointestinal tract. *Clin Gastroenterol Hepatol* 2012;10:603-8.
- Gubler C, Bauerfind P. Endoscopic closure of iatrogenic gastrointestinal tract perforations with the Over-The-Scope-Clip. *Digestion* 2012;85:302-7.
- Heldwein W, Dollhopf M, Rösch T et al. The Munich Polypectomy Study (MUPS): Prospective analysis of complications and risk factors in 4000 colonic snare polypectomies. *Endoscopy* 2005;37:1116-22.
- Magdeburg R, Sold M, Post S et al. Differences in the endoscopic closure of colonic perforation due to diagnostic or therapeutic colonoscopy. *Scand J Gastroenterol* 2013;48:862-7.
- Kim JS, Kim BW, Kim JI et al. Endoscopic clip closure versus surgery for the treatment of iatrogenic colon perforations developed during diagnostic colonoscopy: a review of 115,285 patients. *Surg Endosc* 2013;27:501-4.
- Cho SB, Lee WS, Joo WE et al. Therapeutic options for iatrogenic colon perforation: feasibility of endoscopic clip closure and predictors of the need for early surgery. *Surg Endosc* 2012;26:473-9.
- Jovanovic I, Zimmerman L, Fry LC et al. Feasibility of endoscopic closure of an iatrogenic colon perforation occurring during colonoscopy. *Gastrointest Endosc* 2011;73:550-5.
- Kang HY, Kang HW, Kim SG et al. Incidence and management of colonoscopic perforations in Korea. *Digestion* 2008;78:218-23.
- Taku K, Sano Y, Fu KI et al. Iatrogenic perforation associated with therapeutic colonoscopy: a multicenter study in Japan. *J Gastroenterol Hepatol* 2007;22:1409-14.
- Yang DH, Byeon JS, Lee KH et al. Is endoscopic closure with clips effective for both diagnostic and therapeutic colonoscopy-associated bowel perforation? *Surg Endosc* 2010;24:1177-85.
- Niyashama N, Mori H, Kobara H et al. Efficacy and safety of Over-The-Scope-Clip: including complications after endoscopic submucosal dissection. 2013;19:2752-60.
- Seebach L, Bauerfeind P, Gubler C et al. "Sparing the surgeon": clinical experience with Over-The-Scope-Clips for gastrointestinal perforation. *Endoscopy* 2010;42:1108-11.
- Paspatis GA, Dumonceau JM, Barthet M et al. Diagnosis and management of iatrogenic endoscopic perforations: European Society of Gastrointestinal Endoscopy (ESGE) Position Statement. *Endoscopy* 2014;46:693-711.