

Promising results after endoscopic vacuum treatment of anastomotic leakage following resection of rectal cancer with ileostomy

Nikolaj Nerup¹, John Lykkegaard Johansen², Ghalib Ali Abod Alkhefagie², Pierre Maina² & Kenneth Højsgaard Jensen²

ABSTRACT

INTRODUCTION: In colorectal surgery, the most feared complication is anastomotic leakage (AL), which is associated with a high morbidity and mortality. In this study, we focus on treatment of perianastomotic abscess following AL after low anterior resection (LAR) of rectal cancer. In the literature, conservative irrigation regimes are reported to endure for months and some even years and to be associated with a poor stoma closure rate. In the present paper, we evaluated endoscopic vacuum treatment of the perianastomotic abscess.

MATERIAL AND METHODS: Patients who had LAR due to rectal cancer with total mesorectal excision (TME) performed in Slagelse and Næstved Hospitals in the 2008-2012 (1st February) period were identified in the Danish Colorectal Cancer Group database. We included patients who had AL and who did not require emergency reoperation and were treated with endoscopic vacuum in the study period. Patients who initiated treatment more than one month after the leakage were excluded. All patients had primary ileostomy.

RESULTS: A total of 13 patients were included. All patients had successful closure of the perianastomotic abscess for a median of 18 (3-40) days in a median of eight (1-18) sessions. The median length of hospital stay was 25 (7-39) days. Mortality was zero, and the stoma closure rate was 12/13 (97%).

CONCLUSION: Our data support the positive findings previously reported by other studies. Endoscopic vacuum treatment seems to be a safe approach for selected patients in the treatment of perianastomotic abscess after LAR with TME of rectal cancer.

FUNDING: not relevant.

TRIAL REGISTRATION: not relevant.

may reduce the severity of the leakage [5, 6]. In a randomized multicenter trial, Matthiesen et al showed that a defunctioning ileostomy decreased the rate of symptomatic leakage and recommended it to all LAR cases [4]. Even when a protective ileostomy is present, a large presacral perianastomotic abscess can occur. When the total mesorectal excision (TME) technique is used when performing LAR, the mesorectum is removed and a large cavity is present and any AL may consolidate into an abscess because of the low position of the anastomosis [7].

The treatment of AL depends on the severity of the leakage. If the patient has generalized peritonitis with sepsis, emergency surgery with resection of the anastomosis and creation of a permanent sigmoid colostomy is mandatory [1]. However, if the patient is clinically less affected, other approaches can be considered [7, 8]. The focus of this study was on the treatment of perianastomotic abscess. The present study describes the minimally invasive method of endoscopic vacuum for treatment of the perianastomotic abscess.

This method is an alternative to the protracted and in some cases ineffective treatment with transanal irrigation and drainage. It is shown that some patients treated with the conservative regime may develop chronic, persistent pre-sacral sinuses. This either delays or makes closure of the diverting primary ileostomy impossible [9].

We retrospectively evaluated the endoscopic vacuum treatment of AL after LAR (with TME) of rectal cancer. Our primary end-points were duration of treatment, length of hospital stay, mortality, complications and treatment success.

MATERIAL AND METHODS

Patients who underwent LAR of the rectum at Slagelse or Næstved Hospital in the period from 1st February 2008 to 1st February 2012 were identified using the Danish Colorectal Cancer Group (DCCG) database. Patient records were examined retrospectively. All patients operated with TME-LAR in this period underwent temporary ileostomy, planned to be reversed three months later.

The inclusion criteria were as follows: patients with rectal cancer operated with LAR who developed an

ORIGINAL ARTICLE

1) Department of Surgical Gastroenterology, Hvidovre Hospital
2) Department of Surgery, Slagelse Hospital

Dan Med J
2013;60(4):A4604

In rectal surgery, the most feared complication is anastomotic leakage (AL), which is associated with increased morbidity and mortality during postoperative surgical care [1]. Low anterior resection (LAR) of rectal cancer is associated with relatively high leakage rates which have been shown to range from 10% to 19% [2-4]. In a large prospective multicentre study, Gastinger et al showed that an ileostomy does not protect against ALs [5], but

anastomotic leak and were treated with endoscopic vacuum therapy. According to the DCCG, rectal cancer was defined as a histologically verified cancer with the anal edge 0-15 cm above the external anal opening, measured by rectoscopy [10]. AL was defined as a defect of the intestinal wall integrity at the colo-rectal or colo-anal anastomotic site (including suture and staple lines of neorectal reservoirs) leading to a communication between the intra- and extraluminal compartments. A pelvic abscess close to the anastomosis was also considered an AL. This definition and the following classification were proposed in 2010 by the International Study Group of Rectal Cancer [11]. Leakages were classified into three groups:

- A) AL requiring no active therapeutic intervention
- B) AL requiring active therapeutic intervention but manageable without re-laparotomy
- C) AL requiring re-laparotomy.

Patients presented symptoms and signs of leakage such as sepsis, fever, elevated white cell count and C-reactive protein, perineal or pelvic pain, localized or generalized peritonitis and discharge of blood or puss per rectum. AL was diagnosed by computed tomography (CT) with intravenous contrast. Generalized peritonitis following leakage was the primary criterion for re-laparotomy (group C). Our study focused on group B leakages.

The exclusion criteria were late onset endoscopic vacuum treatment more than one month after leakage diagnosis and patients who had not completed treatment at 1 February 2012. Patients with AL who required re-laparotomy (group C) were also excluded.

Endoscopic vacuum treatment

We used the Endo-Sponge (B. Braun Medical B.V., Melsungen, Germany), an open-pore sponge which communicates with a suction drain connectable to a vacuum bottle. This ensures that negative pressure is maintained and that puss and fluids produced by the abscess are collected. The procedure begins with a flexible sigmoidoscopy with the patient in the left lateral position and it can be performed without analgesia, alternatively under light sedation. The leakage in the anastomotic line is found and dilated. Then the abscess cavity is localized and measured with the scope. Next, the sponge is adapted; if the cavity is large, more than one sponge may be used. Now the scope is introduced with an over-tube, which is left in the top of the cavity, and the scope is removed. Subsequently, the sponge is inserted through the over-tube and the tube can be removed. The sponge position is controlled endoscopically, and the sponge is connected to the vacuum-container to establish vacuum. The sponge is changed every second or

third day, each time trimmed so that the cavity is reduced [7, 8, 12]. We ceased treatment when the cavity was about 3 cm wide and covered with granulation tissue. Treatment beyond this point is limited by formation of the sponge. The method is based on the principles known from the vacuum-assisted closure (VAC)-treatment of wounds. VAC treatment accelerates wound healing and is used extensively for open wound management. The mechanism of accelerated healing is probably owed to an increased vascularity and formation of granulation tissue which reduces the risk of bacterial colonization [13]. In experimental animal studies of wound management, vacuum-assisted closure has been shown to induce healing by maintaining continuous decontamination, increased microcirculation and improved granulation [14].

The endoscopic vacuum treatment also enhances formation of granulation tissue and increases vascularity [7, 8, 12, 15, 16]. The cavity is filled with the vacuum sponge so that further contamination from the colon is blocked and the negative pressure will lead to mechanical reduction of the cavity [12]. For illustration, please see **Figure 1**.

Informed consent was obtained from all patients before initiation of endoscopic vacuum treatment.

Trial registration: not relevant.

RESULTS

A total of 232 patients had undergone LAR for rectal cancer in the given four year period. Thirty-two patients (14%) were identified as having had an AL. Fifteen (47%) of the patients with leaks were not reoperated due to minor symptomatology and clinical findings, and they were only treated with endoscopic vacuum therapy. Two patients were excluded. The first had one previous treatment attempt but had been unable to cooperate due to psychiatric disease. The second patient initiated endoscopic vacuum treatment three months postopera-

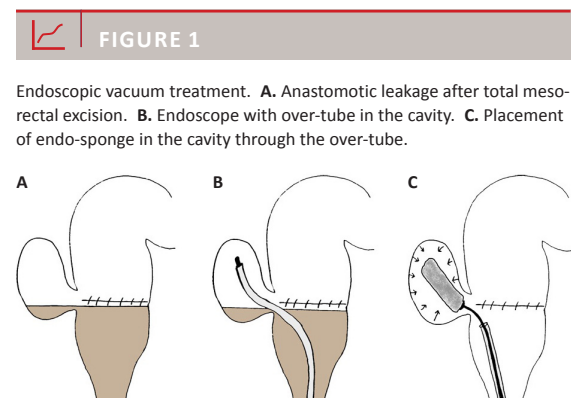




TABLE 1

Patient characteristics.

Male, n (%)	11 (85)
Age, years, median (range)	64 (36-71)
Body mass index, kg/m ² , median (range)	26 (22-32)
ASA classification, n (%)	
I	4 (31)
II	9 (69)
TNM stage, n (%)	
T2N0M0	2 (15)
T2N2M0	1 (8)
T3N0M0	4 (31)
T3N1M0	3 (23)
T3N2M0	2 (15)
T4N0M0	1 (8)
Tumour distance from anus, cm, median (range)	9 (6-12)
Primary ileostomy, n (%)	13 (100)
Neoadjuvant radiotherapy, n (%)	6 (46)
Approach, n (%)	
Laparotomy	12 (92)
Laparoscopy	1 (8)

ASA classification = American Society of Anesthesiologists physical status classification system.

TNM = tumour-node-metastasis.

tive and only had two treatments with minimal effect. This patient is not included in this study due to its late start and therefore incomparable efficacy of the treatment. Both patients were transferred to conservative treatment with irrigation. Thirteen patients were included in the study group.

For patient characteristics, please see **Table 1**.

All 13 patients treated with endoscopic vacuum achieved successful healing of the perianastomotic abscess cavity. The median length of hospital stay was 25 days (7-39 days). Some continued treatment in an outpatient setting. The median number of treatments per patient was eight (1-18). The endoscopic vacuum treatment continued for a median of 18 days (3-40 days). None of the patients died during treatment. One patient developed a 10-cm long colon stenosis from the anastomotic site and proximally after an otherwise successful endoscopic vacuum treatment. The patient was reoperated and a permanent colostomy was established. The stoma closure rate of the entire study group was 12/13 (92%). No other complications were observed.

DISCUSSION

In our selected group of patients who underwent TME-LAR with AL, we had a success rate of 13/13 (100%) with regard to healing of the perianastomotic abscess cavity using endoscopic vacuum treatment. A similar result was achieved by Weidenhagen et al who treated 29 patients with 28/29 (97%) successful treatments [12]; and

Glitsch et al reported successful endoscopic vacuum treatment in 16/17 (94%) treated patients [8]. But von Bernstorff et al had success in 2,326 (88%) patients [15], and in the study by van Koperen et al only 9/16 (56%) treatments enjoyed a successful outcome [16]. The reason for the low rate of success in the study by van Koperen et al was probably that treatment was offered not only to patients with "fresh leakages", but also to patients with chronic sinuses up to 1,600 days after initial surgery [16]. An explanation of our good results may be the limited number of patients, but also the fact that our study group was very homogenous. We initiated therapy soon after leakage and restricted treatment to patients with consolidated abscesses, no signs of generalized peritonitis, AL after low anterior rectum resection with TME technique of rectal cancer, and all our patients had a diverting ileostomy.

Complications to endoscopic vacuum treatment are limited. In our study, we only had one possible complication: a stenosis at the anastomotic site. Other complications reported are pain and bleeding from the cavity when changing the sponge [16]. Furthermore, there have been reports on patients with recurrent abscesses and development of large systems of interenteric fistulas [15]. Contact of the sponge with the small or large intestine should be avoided. Risks of complications include fistula formation to other parts of the intestines, the urine bladder and the vagina. If the patient shows signs of fistula formation, treatment should be stopped and a fistulography or and magnetic resonance imaging should be performed [12]. Furthermore, though this has not been reported, sepsis or necrosis may be a risk if the sponge is left more than the recommended maximum of three days before replacement, similar to the toxic shock syndrome [17]. There are no reports on tumour relapse as a complication to endoscopic vacuum treatment.

The mortality seems to be low during treatment with endoscopic vacuum. Only Weidenhagen et al reported two deaths during treatment, both had advanced cancer [12]; otherwise, studies on endoscopic vacuum treatment have reported no mortality.

The length of hospital stay in our study was a median of 25 days (7-39 days), which is less than the previously reported mean stays of 41 [15], 40 [16] and 34 days [12]. We continued treatment for a median of 18 days (3-40 days). This is also shorter than the mean periods reported in previous studies: 21.5 [15] and 34 days [12]. The reason for this could be the decision of when to cease treatment. We ended treatment when the cavity was about 3 cm wide, where as Weidenhagen et al terminated treatment at a cavity size of 0.5 cm × 1.0 cm [12]. When treatment should be terminated remains unclear.

The treatment period seems to be shorter than that of conservative irrigation treatment. Patients with perianastomotic abscesses treated in our department before endoscopic vacuum treatment was introduced could be seen for several months and some even several years with puss-producing abscesses. This observation is supported by the literature. Van Kooperen reported that if the perianastomotic abscess develops to a persistent presacral sinus, only half of the 23 patients (52%) in the study group had definitive resolution of the sinus when conservatively treated with irrigation. This was achieved at a median of 340 days (23-731 days). At the final follow-up, nine (39%) had permanent stoma due to recurrent abscesses or persistent sinus [9]. However, a comparative study of conservative versus endoscopic vacuum treatment is needed to establish if endoscopic vacuum treatment is superior to the conservative transanal irrigation regime.

Endoscopic vacuum treatment may be done in an outpatient setting. There are few hygienic problems and odour nuisances for the patient and his/hers surroundings. Furthermore, the patient can benefit from a quick return to normal life and work, leading to reduced costs for both patient and society [12].

Weidenhagen et al [12] and von Bernstorff et al [15] both showed that a diverting ileostomy is not a prerequisite to completion of endoscopic vacuum treatment. However, treatment is more difficult without a diverting ileostomy, and the vacuum canister could lose pressure more quickly because of the intraluminal gas, and may need changing more often. Furthermore, having a plastic tube placed in the anal opening while having normal gastrointestinal function may cause hygiene problems. As noted, all our patients had a diverting ileostomy.

Von Bernstorff found that endoscopic vacuum treatment leads to complete, but delayed closure of the perianastomotic abscess following neoadjuvant chemoradiotherapy [15]. We did not observe similar results among the six patients (47%) in the present study who had neoadjuvant radiotherapy.

It was indicated by Van Koperen that the earlier endoscopic vacuum treatment is initiated after leakage, the better the results and the fewer the complications. Furthermore, treatment should not be prolonged if no sign of progression is observed [16]. This is supported by the study of Weidenhagen et al [12], where patients undergoing LAR of rectal cancer were followed closely postoperatively. The anastomosis was investigated routinely by endoscopy if patients showed any symptoms or signs of leakage. If a leak was present, it was treated with endoscopic vacuum treatment and the results were remarkable. Twenty-eighth of 29 patients had successful endoscopic vacuum treatment of their perianastomotic abscess [12].

Some of these patients, however, may have had leaks that did not require treatment and should possibly not have been treated this aggressively. Comparative studies to determine the gold standard in treatment of all types of anastomotic leaks have yet to be performed. The optimal way to use the endoscopic vacuum treatment also remains undetermined, also regarding the need for a diverting stoma.

In conclusion, it seems that endoscopic vacuum treatment can be used as a safe and feasible approach for selected patients to treat perianastomotic abscess after LAR with TME of rectal cancer.

CORRESPONDENCE: Nikolaj Nerup, Gastroenheden, Kirurgisk Sektion, Hvidovre Hospital, 2650 Hvidovre, Denmark. E-mail: nikolajnerup@gmail.com.

ACCEPTED: 5 February 2013

CONFLICTS OF INTEREST: Disclosure forms provided by the authors are available with the full text of this article at www.danmedj.dk

LITERATURE

1. Mileski WJ, Joehl RJ, Rege RV et al. Treatment of anastomotic leakage following low anterior colon resection. *Arch Surg* 1988;123:968-71.
2. Dixon AR, Maxwell WA, Holmes JT. Carcinoma of the rectum: a 10-year experience. *Br J Surg* 1991;78:308-11.
3. Paun BC, Cassie S, MacLean AR et al. Postoperative complications following surgery for rectal cancer. *Ann Surg* 2010;251:807-18.
4. Matthiessen P, Hallböök O, Rutegård J et al. Defunctioning stoma reduces symptomatic anastomotic leakage after low anterior resection of the rectum for cancer: a randomized multicenter trial. *Ann Surg* 2007;246:207-14.
5. Gastinger I, Marusch F, Steinert R et al. Working Group Colon/Rectum Carcinoma. Protective defunctioning stoma in low anterior resection for rectal carcinoma. *Br J Surg* 2005;92:1137-42.
6. den Dulk M, Marijnen CA, Collette L et al. Multicentre analysis of oncological and survival outcomes following anastomotic leakage after rectal cancer surgery. *Br J Surg* 2009;96:1066-75.
7. Verlaan T, Bartels SA, van Berge Henegouwen MI et al. Early, minimally invasive closure of anastomotic leaks: a new concept. *Colorectal Dis* 2011;13:18-22.
8. Glitsch A, von Bernstorff W, Seltrecht U et al. Endoscopic transanal vacuum-assisted rectal drainage (ETVARD): an optimized therapy for major leaks from extraperitoneal rectal anastomoses. *Endoscopy* 2008;40:192-9.
9. van Koperen PJ, van der Zaag ES, Omloo JM et al. The persisting presacral sinus after anastomotic leakage following anterior resection or restorative proctocolectomy. *Colorectal Dis* 2011;13:26-9. doi: 10.1111/j.1463-1318.2010.02377.x.
10. Kirurgisk behandling af cancer recti: http://dccc.dk/retningslinjer/2010_rectumkirgenerelt.pdf (1 Jan 2013).
11. Rahbari NN, Weitz J, Hohenberger W et al. Definition and grading of anastomotic leakage following anterior resection of the rectum: A proposal by the International Study Group of Rectal Cancer. *Surg* 2010;147:339-51.
12. Weidenhagen R, Gruetzner KU, Wiecken T et al. Endoscopic vacuum-assisted closure of anastomotic leakage following anterior resection of the rectum: a new method. *Surg Endosc* 2008;22:1818-25.
13. Argenta LC, Morykwas MJ. Vacuum-assisted closure: a new method for wound control and treatment: clinical experience. *Ann Plast Surg* 1997;38:563-76.
14. Morykwas MJ, Argenta LC, Shelton-Brown EI et al. Vacuum-assisted closure: a new method for wound control and treatment: animal studies and basic foundation. *Ann Plast Surg* 1997;38:553-62.
15. von Bernstorff W, Glitsch A, Schreiber A et al. ETVARD (endoscopic transanal vacuum-assisted rectal drainage) leads to complete but delayed closure of extraperitoneal rectal anastomotic leakage cavities following neoadjuvant radiochemotherapy. *Int J Colorectal Dis* 2009;24:819-25.
16. van Koperen PJ, van Berge Henegouwen MI, Rosman C et al. The Dutch multicenter experience of the endo-sponge treatment for anastomotic leakage after colorectal surgery. *Surg Endosc* 2009;23:1379-83.
17. Reingold AL. Toxic shock syndrome: an update. *Am J Obstet Gynecol* 1991;165:1236-9.