

No clinical value of post-operative routine X-ray following uncomplicated cementless primary total hip arthroplasty

Mikkel Christensen & Klaus Folkmar

ABSTRACT

INTRODUCTION: There is no consensus among hip surgeons in Denmark on how to follow up patients after total hip arthroplasty (THA). Agreement on the need for radiographic examinations is also lacking. The purpose of this study was to evaluate if routine outpatient post-operative radiographs, obtained three and 12 months after uncomplicated cementless primary THA influenced patient treatment.

MATERIAL AND METHODS: A retrospective chart review was performed for 249 cases who had received THA during a four-month period. Patient data, indication for surgery and type of prosthesis were noted. The radiographic descriptions in the medical record made by the operating surgeon at the three- and 12-month outpatient follow-up visits were examined.

RESULTS: At three months, the radiograph showed subsidence ranging from "barely detectable" to ten millimetres in eight of 216 cases. One patient was treated with crutches. The remaining three patients were given another follow-up visit. At 12 months, two cases had signs of stress shielding with cortical thickening. This had no consequence in one patient and the other was given additional follow-up.

CONCLUSION: We conclude that routine radiographs can be omitted from the outpatient follow-up within the first year following primary elective cementless THA as it does not affect treatment. We believe radiographs should be reserved for patients with subjective complaints such as pain and to those who are referred outside the routine follow-up plan due to complications.

FUNDING: not relevant.

TRIAL REGISTRATION: not relevant.

There is no consensus among hip surgeons in Denmark on follow-up after total hip arthroplasty (THA). Some follow their patients with several outpatient office visits during the first year. Others do not routinely see their patients again after discharge.

A few studies have focused on the value of routine outpatient radiographic examination following cemented arthroplasty and concluded that routine radiographs had no consequence for treatment and should only be done on clinical indication [1, 2]. No study has examined if this also applies to cementless arthroplasty.

It is believed that regular follow-up with radiographic examination identifies the patient at risk of failure. The current literature offers little insight into the effectiveness of these screening tests in detecting abnormalities that require surgical intervention or alteration of rehabilitative therapy in patients with primary THA.

In our clinic, we routinely obtain post-operative radiographs of the relevant hip in two projections. Radiographs are taken before discharge, and at three and 12 months after cementless primary THA. To minimize radiation exposure and use resources as efficiently as possible, we have chosen to focus on outpatient radiographic examination during follow-up.

The purpose of this study was to evaluate if routine outpatient post-operative radiographs obtained three and 12 months after uncomplicated cementless primary THA had any influence on treatment.

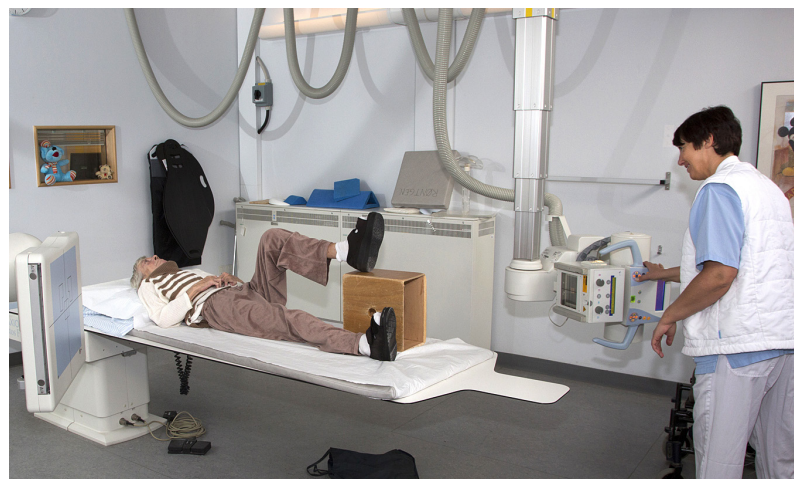MATERIAL AND METHODS

A retrospective chart review was performed for all patients undergoing cementless primary THA from August to November 2009 at Hørsholm Hospital, Orthopaedic Hip Clinic. In the study period, 246 primary THAs were performed. In ten cases, a cemented technique was used. The population receiving cementless THA counted

ORIGINAL ARTICLE

Orthopaedic Department, Hillerød Hospital

Dan Med J
2013;60(4):A4613



Radiographic examination of the hip.

152 women and 84 men. The mean age was 68 years (26 to 93 years). The main indication was osteoarthritis (OA) (n = 215; 91%). Other indications were dysplasia (n = 10; 4%), sequelae from fracture (n = 6; 2.5%), rheumatoid arthritis (n = 4; 1.7%) and caput necrosis (n = 1; 0.4%). In all cases, a posterolateral approach was used. In 201 cases, a CLS Spotorno femur stem (Zimmer) was used, and in the remaining 35 cases a Bi-Metric femur stem (Biomet) was used combined with a cementless Trilogy cup (Zimmer) or a cementless Harris-Galante cup (Zimmer) with or without additional screw fixation.

All procedures were performed in a clean-air operating theatre with laminar airflow. All patients received prophylactic antibiotics during the procedure (1,500 mg Zinacef, GlaxoSmithKline Pharma) and were treated with antithrombotic prophylaxis post-operatively (4,500 IE Innohep, Leo). Unrestricted weight-bearing was allowed.

To avoid dislocations, the patients were instructed not to cross their legs, bend the hip by more than 90 degrees, or internally rotate the hip.

Patient data, indication for surgery and type of prosthesis were noted. The radiographic description in the medical record made by the operating surgeon at the three- and 12-month outpatient follow-up visit was examined. Any mention of subsidence, cortical thickening, fissures, fractures, position of implants, and loosening of the implant as described in the records were noted.

Patients with major per- or post-operative complications such as fracture, deep infection, or dislocation and cases requiring bone transplantation were excluded. Patients having complaints that led to early referral and additional outpatient follow-up outside of the planned three- and 12-month follow-up visits were also excluded. Any event during the planned three- and 12-month outpatient visits was counted as a positive endpoint provided the event led to additional outpatient follow-up visits, weight bearing restriction, or any change in treatment strategy provided that abnormalities were also present in the radiograph. Patients with lacking data were excluded.

A telephone survey was conducted to illustrate the extent of the use of routine radiographs. Departments who performed more than 100 THAs in 2011 were interviewed. Rigshospitalet and private hospitals were not included in the survey as Rigshospitalet has a specialized role treating complicated cases, and an economic incentive is present for private hospitals. A call was made to either the senior doctor on call or the senior doctor responsible for arthroplasty. Interviewees were asked if their department performed routine follow-up in uncomplicated elective primary cases. If the answer was affirmative, we also asked if follow-up included routine radiographs.

Confidence intervals for the number of positive endpoints were calculated using the Clopper-Pearson exact method for confidence intervals on binomial distributions.

Trial registration: not relevant.

RESULTS

A total of 11 patients were excluded before the three-month follow-up visit; seven patients had fractures, four of which occurred during surgery. The remaining four patients had major post-operative complications requiring revision; two had loosening of the cup and two had deep infection. At three months, 225 patients received follow-up. The results are presented in **Figure 1**.

One patient had fallen between the two outpatient visits and had suffered a trochanteric fracture and was

FIGURE 1

Outcome of 3-month follow-up.

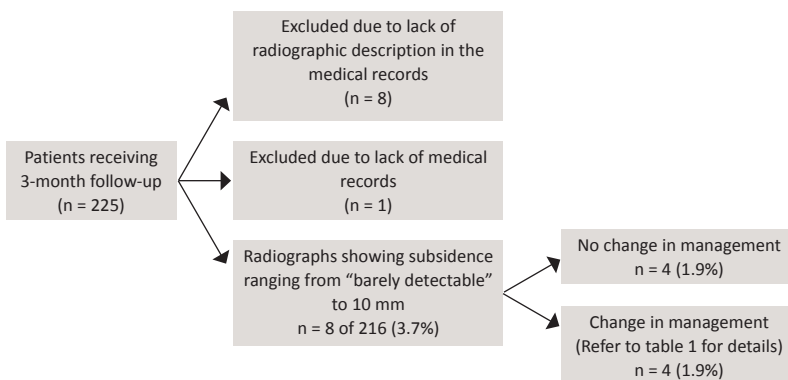


FIGURE 2

Outcome of 12-month follow-up.

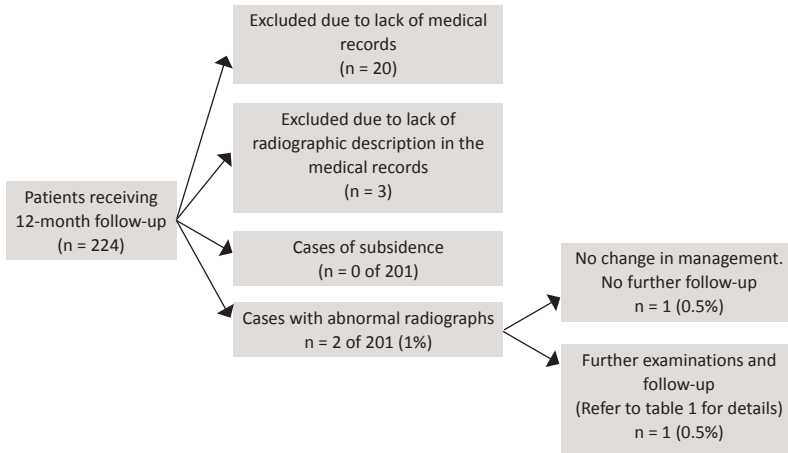




TABLE 1

Summary of cases in which radiographs resulted in a change of treatment.

3-month follow-up		12-month follow-up	
clinical presentation and radiograph description	change of treatment and description of additional follow-up radiograph	clinical presentation and radiograph description	change of treatment
1 Weight-bearing pain Radiograph shows signs of healed fissure 5-10 mm subsidence	No weight-bearing restriction Additional follow-up at 6 months revealed no further subsidence	No further problems Radiographs shows no further subsidence	No change in treatment Patient received no further follow-up
2 Weight-bearing pain Radiographs shows subsidence of 2-3 mm	Reduced weight-bearing for 6 weeks using crutches Additional follow-up at 6 weeks revealed no further subsidence	No further problems Radiographs show no further subsidence	No change in treatment Patient received no further follow-up
3 No subjective complaints Radiographs shows subsidence of 10 mm	No weight-bearing restriction Additional follow-up at 4 months revealed no further subsidence	No further problems Radiographs show no further subsidence	No change in treatment Patient received no further follow-up
4 No subjective complaints Radiographs shows subsidence of 3-4 mm	No weight-bearing restriction Additional follow-up at 6 months revealed no further subsidence	No further problems Radiographs show no further subsidence	No change in treatment Patient received no further follow-up
5 Experience of pain Radiographs show nothing abnormal	No change in treatment	Ongoing pain Radiographs show signs of stress shielding with cortical thickening	A scintigraphy was performed, ruling out infection The patient still suffers from pain 3 years later Pain is unrelated to the THA

THA = total hip arthroplasty.

thus excluded at the 12-month follow-up. The results from the 12-month follow-up are presented in **Figure 2**.

The cases in which the radiograph aided in changing treatment are summarized in **Table 1**.

The results of the telephone survey are shown in **Table 2**.

Among 417 outpatient visits, the radiographic examination had direct consequence in five cases (1.2%; 95% confidence interval (CI): 0.4-2.8%); however, in only two cases (0.48%; 95% CI: 0.06-1.72) did the radiographs result in consequences other than increased follow-up. One was given a regime of partial weight-bearing for six weeks, while the other was examined further due to a suspected infection. Both of these patients were experiencing pain.

DISCUSSION

According to National Danish Guidelines on Hip Replacement published by the Danish Society of Orthopaedic Surgeons, radiographs are not indicated within the first year, aside from the immediate post-operative radiograph [3]. Despite this, approximately one in three clinics in Denmark still makes routine radiographic examinations during the outpatient follow-up (Table 2).

Patient follow-up and radiographs are considered an important aspect of quality control [4, 5]. The outpatient programme serves several purposes. The patient may achieve a sense of safety and the surgeon may evaluate the outcome of his or her work [1, 2, 6]. Studies have also shown that patients are generally interested in outpatient follow-up visits [3]. The most common problems experienced after discharge are lack of healing,

problems with rehabilitation and leg-length discrepancy [2]. Apart from the latter, these conditions are diagnosed and treated clinically and no radiograph is needed. In our study, we questioned the use of routine radiographs at three and 12 months.

Some degree of subsidence is considered normal [7]. Routine radiography did reveal several cases with varying degrees of subsidence, but all were without consequence as no further subsidence was detected at the subsequent follow-up. The resulting leg-length discrepancy could be screened in a clinical setting initially without the use of radiographs [2, 8]. Radiographs could then be reserved for those with clinical suspicion of leg-length discrepancy.

Clinical findings will often be more important in determining patient management than radiographs. Surgeons will often not revise a THA on radiographic information alone [9]. Tigges et al [9] examined this by investigating the consequence of radiographs in outpa-



TABLE 2

Departments in Denmark which perform routine radiographs within the first year.

Region	Routine radiographs	No routine radiographs
Capital of Denmark	3	4
Central Jutland	3	3
Northern Jutland	0	3
Zealand	0	4
Southern Denmark	2	4
Total	8	18

tient follow-up. A senior surgeon evaluated each of his follow-up outpatients (n = 175) before reviewing the accompanying radiographs. After the surgeon made and recorded his patient treatment plan based on the clinical evaluation, he reviewed the radiographs for findings of failure and recorded any resulting change in management plan. In only one patient did the radiographic findings change clinical management. The authors also concluded that patients can be divided into two categories: symptomatic and asymptomatic. Most, if not all, patients with complications will experience some degree of pain. Similar findings were reported by Hacking et al [10], who examined the cause of 110 THA revisions in a four-year period. The authors found all patients requiring revision to be experiencing pain. It was also noted that in none of the 110 cases requiring revision did routine elective follow-up of primary THAs result in detection and subsequent revision of an asymptomatic joint.

A feared and serious complication to THA is aseptic loosening. This condition can often be silent and completely asymptomatic – until failure. The resulting bone loss from resorption often leaves very little left to work with, which complicates revisions. There is, however, little danger of overlooking cases of aseptic loosening by omitting radiographs within the first year as this condition typically presents several years after surgery [6, 11, 12].

However, our material might be subject to bias as the quality of a retrospective chart review is no better than the quality of the records. This is reflected in the lack of a systematic description of the radiographs in the records. Important information from the radiographs could, in theory, have been used to adjust treatment, but could have been omitted from the medical records. It is difficult to quantify to which extent the radiographs aided in the decision to do additional follow-up or adjust the treatment plan. Prospective clinical trials with standardized recording of patient symptoms and standardized description of radiographs are needed to validate our findings.

The fact that already at the three-month follow-up the patients were scheduled for a 12-month follow-up may also be a factor that affects the decision to provide additional follow-up. One might argue that the four patients who did not receive additional follow-up at 3 months might have, if they had not already been scheduled for follow-up at 12 months.

In our clinic, we use a cementless technique on a very broad indication. The cemented technique is mainly reserved for the severely osteoporotic patients. According to the Danish Hip Arthroplasty Register in 2009, a total of 67.4% of primary THA were cementless [13]. In our clinic, 95.9% were cementless. The resulting bias, however, is skewed in favour of our study as we

chose to utilize a cementless technique where others might have chosen cemented technique – and despite this, we still experienced no consequence from routine radiographs.

Some degree of selection bias may also be present as OA was the indication in 91% of the cases in our population. This is slightly more than the 81% reported in Denmark by the Danish Hip Arthroplasty Register in 2009, which suggests that some form of selection took place. This is probably because Hørsholm Hospital, Orthopaedic Hip Clinic is reserved for the less complicated cases as the clinic is an elective unit with restricted intensive capacity.

We conclude that routine outpatient radiographs obtained three and 12 months after uncomplicated cementless primary THA has no clinically significant influence on treatment. We propose that routine radiographs be omitted from the outpatient follow-up within the first year following primary elective uncomplicated cementless THA. We believe radiographs should be reserved for patients with subjective complaints such as pain and for patients referred outside the routine follow-up plan due to complications [14].

CORRESPONDENCE: Mikkel Christensen, Abildvang 86, 2700 Brønshøj, Denmark. E-mail: jmmikkel@hotmail.com

ACCEPTED: 19 February 2013

CONFLICTS OF INTEREST: none. Disclosure forms provided by the authors are available with the full text of this article at www.danmedj.dk.

LITERATURE

1. Niskanen RO. Early repetitive radiography is unnecessary after an uncomplicated cemented hip or knee arthroplasty for osteoarthritis. *Acta Orthop Belg* 2005;71:692-5.
2. Hoffmann P, Röck ND, Frandsen PA. Therapeutic consequences of an ambulatory follow-up program following Charnley hip joint alloplasty. *Ugeskr Læger* 1987;149:3319-22.
3. www.ortopaedi.dk/fileadmin/referenncprogram/THA-referenceprogram.pdf (15 Dec 2012).
4. Ververeli PA, Masonis JL, Booth RE et al. Radiographic cost reduction strategy in total joint arthroplasty. *J Arthroplasty* 1996;11:277-80.
5. Glaser D, Lotke P. Cost-effectiveness of immediate postoperative radiographs after un-complicated total knee arthroplasty: a retrospective and prospective study of 750 patients. *J Arthroplasty* 2000;15:475-8.
6. Overgaard S, Jensen TT, Møssing N. The value of 1-year follow-up after total cemented hip alloplasty. Clinical and economic consequences of a routine check-up. *Ugeskr Læger* 1989;151:1746-8.
7. Mulcahy H, Chew FS. Current concepts of hip arthroplasty for radiologists: part 1, features and radiographic assessment. *AJR Am J Roentgenol*. 2012;199:559-69.
8. Sabharwal S, Kumar A. Methods for assessing leg length discrepancy. *Clin Orthop Relat Res* 2008;466:2910-22.
9. Tigges S, Roberson JR, Cohen DE. Hip arthroplasty: the role of plain radiographs in out-patient management. *Radiology* 1995;194:73-5.
10. Hacking C, Weinrauch P, Whitehouse SL et al. Is there a need for routine follow-up after primary total hip arthroplasty? *ANZ J Surg* 2010;80:737-40.
11. Katz RP, Callaghan JJ, Sullivan PM et al. Long-term results of revision total hip arthroplasty with improved cementing technique. *J Bone Joint Surg Br* 1997;79:322-6.
12. Allami MK, Fender D, Khaw FM et al. Outcome of Charnley total hip replacement across a single health region in England. *J Bone Joint Surg Br* 2006;88:1293-8.
13. www.dhr.dk/Ny%20mappe/rapporter/DHR%20Aarsrapport_2010%20t_web.pdf (15 Dec 2012).
14. Lee AJ, Lim SS, Kong Y et al. Cost-effectiveness of screening x-rays at admission to acute rehabilitation after joint replacement surgery: a retrospective chart review. *Am J Phys Med Rehabil* 2001;80:276-9.