

# Asymptomatic body packers should be treated conservatively

Peter V. Glovinski, Morten L. Lauritsen, Morten Bay-Nielsen, Birgitte Brandstrup & Thue Bisgaard

## ABSTRACT

**INTRODUCTION:** Body packing takes advantage of the human storage capacity within the alimentary tract. Body packing is used for the smuggling of drugs such as heroin, cocaine, amphetamine, hashish and ecstasy. Most body packers are asymptomatic. However, packets may rupture or obstruct the alimentary tract. Preventive surgery has been recommended for body packers with package retention beyond 5-7 days to prevent the serious consequences of leakage and rupture. The purpose of the present study was to evaluate a conservative protocolled approach to body packers.

**MATERIAL AND METHODS:** We retrospectively registered all patients suspected of body packing who were brought to a department of surgical gastroenterology. The study comprised a two-year study period from 1 March 2011 to 28 February 2013.

**RESULTS:** A total of 57 patients suspected of body packing were detained and admitted to a hospital. In 29 (53%) of the patients, body packing was confirmed by CT. All 29 body packers were successfully treated conservatively without surgical or endoscopic intervention. The median number of packages ingested was 55 (range 2-120). The body packers were all foreigners and originated from either Eastern Europe or West Africa. In one patient, body packages were retained for 17 days. None of the body packers underwent emergency operation or had signs of rupture.

**CONCLUSION:** Body packers can be treated conservatively unless there is clinical suspicion of acute obstruction, perforation or intoxication. Package retention per se is not an indication for emergency operation.

**FUNDING:** not relevant.

**TRIAL REGISTRATION:** not relevant.

Body packing is a smuggling method using concealment of packets within human cavities/alimentary tract [1]. Body package smuggling has existed for the past 40 years [2]. Body packing is mostly accomplished by ingesting drug-packages, most commonly containing cocaine, heroin, amphetamine, hashish or ecstasy, and let them pass through the gastrointestinal system. Body packers can also hide drug-packages by primary insertion into the vagina or rectum. The medical concern associated with body packing is the risk of gastrointestinal obstruction and package rupture. Acute obstruction re-

quires emergency operation [3], and rupture causes acute intoxication, and eventually risk of death known as the body packer syndrome [4]. Thus, although evidence is weak, surgical intervention has been recommended in cases of package retention beyond 5-7 days to prevent package leakage, rupture and obstruction [3, 5, 6].

The present study was undertaken to evaluate the use of a standard protocol using a conservative strategy for the clinical handling of persons suspected of body packing.

## MATERIAL AND METHODS

Data for all suspected and confirmed body packers were collected retrospectively from a two-year period (1 March 2011 to 28 February 2013). Patients were admitted to the Department of Surgical Gastroenterology, Hvidovre Hospital (Denmark). To identify all patients, a list of suspected body packers was retrieved from the Department of Customs & Tax at Copenhagen International Airport. Furthermore, identification was made by a journal search on International Classification of Diseases (ICD) 10-codes in which discharge papers referred to patients admitted with foreign bodies in their gastrointestinal tract. Also, a free text search of the terms "body" + "pack" contained within any electronic patient record in the study period was performed (**Figure 1**). All patient files were reviewed, and we included both suspected and confirmed body packers in the study. Individuals suspected of body packing were all detained at Copenhagen International Airport. They were guarded by the police and admitted to the hospital until the suspicion of body packing was clarified.

All suspected patients followed a standard protocol. Identification of body packing was done by non-contrast abdominal CT. If packages were identified, the patient was admitted and monitored using a scope. Patients were then treated with an oral laxative containing polyethylene glycol under constant police surveillance, including surveillance during toilet visits. After two package-free stools, a re-CT was performed. If the CT scan was without packages, the body packer was considered to be clean from packages and discharged for further legal action. According to the protocol, emergency surgery was only performed in case of obstruction or signs of intoxication (possible rupture).

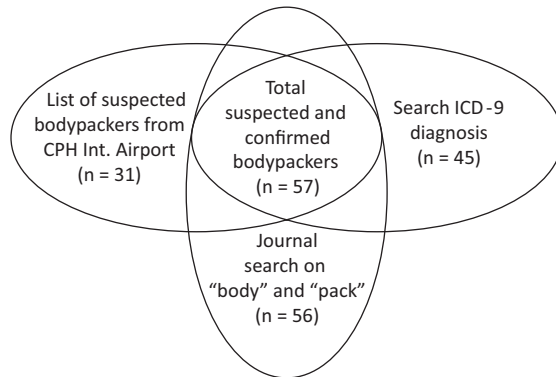
## ORIGINAL ARTICLE

Department of Surgical Gastroenterology, Hvidovre Hospital

Dan Med J  
2013;60(11):A4723


**FIGURE 1**

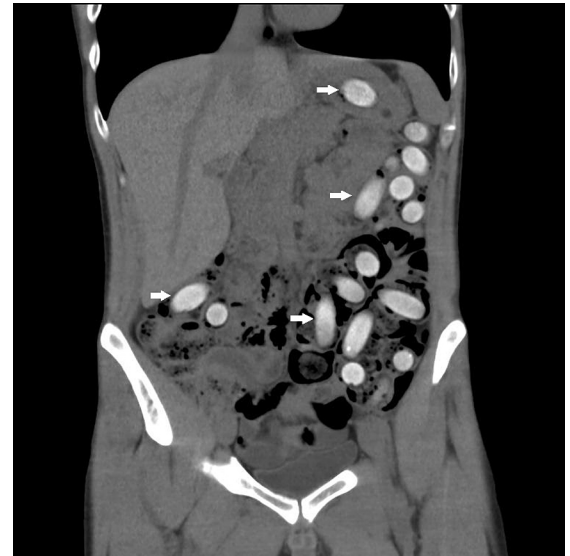The suspected and confirmed body packers (n = 57) were found using a combination of three different types of search methods. Suspected body packers were included either by information from Customs & Tax at Copenhagen International Airport (n = 31), an International Classification of Diseases, nine journal search for patients with foreign bodies in the alimentary tract (n = 45), or a free text search for the words "body" and "pack" in any electronic patient record (n = 56).



CPH = Copenhagen  
ICD = International Classification of Diseases


**FIGURE 2**

A CT showing multiple intra-abdominal foreign bodies (arrows) in a male body packer.



### Statistics

Data analysis was purely descriptive. Data are presented as medians and ranges for all variables (number of packages, length of hospital stay, number of CTs and amount of drugs).

*Trial registration:* not relevant.

### RESULTS

During the study period, 57 suspects were identified as potential body packers (Figure 1). The median age of all detainees was 34 years (range 24-45 years). A total of 29 persons were confirmed body packers by conventional non-contrast CT (Figure 2). Three additional patients from the free text search were described as body stuffers (which is defined as the hasty oral or rectal intake of small amounts of loosely packed drugs to evade law enforcement [7]). These three suspects were excluded from the analysis. From the ICD-10 search, 33 patients were excluded since they had other types of foreign bodies in their gastrointestinal system than drug packages.

All body packers were successfully treated conservatively with oral laxatives (MoviPrep) and none of the body packers underwent emergency operation or other invasive treatments.

The median length of hospital stay was two days (range 1-17 days), and the median number of CTs per body packer was two (range 1-5 CTs). Two of the body packers were symptomatic at the time of admission and both reported abdominal discomfort, but recovered

spontaneously. None of the body packers showed any signs of acute intoxication at any time. All body packers originated from either West Africa or Eastern Europe.

Of the 29 confirmed body packers, 18 carried cocaine (median 497 g, range 60-1.200 g), five carried heroin (median 588 g, range 400-982 g), two carried hashish (range 700-1.200 g) and three of the body packers had packages of both cocaine and heroin. The drug weight of each package ranged from 9.5-15.6 g with a median of 10.2 g per package. In seven of the body packers, information regarding the total amount of drug or the type of drug smuggled was not available. The median number of packages concealed by the body packers was 55 (range 2-120 packages), and all reported that they had concealed the packages by oral ingestion.

One body packer concealed 69 containers of heroin (658 g) and actively held back packages despite supervised bowel movements, which called for hospital admission for 17 days before the gastrointestinal tract was cleared of all packages. Despite of the prolonged period of package retention, the patient was treated conservatively with the oral laxative MoviPrep like all the other patients. The patient had no other objective or radiologic signs of intestinal obstruction or intoxication during admission and recovered uneventfully.

### DISCUSSION

The present study showed good results using a conservative strategy, and this retrospective study indicates that the regimen is safe.

Our findings are consistent with previous studies on body packing. Internationally, the incidence of body packing is described as dramatically increasing [8]. As a method of smuggling, body packing will most likely be a continuing challenge in the future as criminals are able to transport large amounts of drugs (1-2 kg) representing a high price at a low risk of complication. Customs are challenged by the fact that they possess no effective tool to detect drugs inside the body packer and suspects are therefore often detained on the grounds of general suspicion.

In the present study, no adverse events occurred in any of the body packers despite the fact that one patient had heroin package retention for 17 days. Previous studies have recommended surgery in body packers with retention beyond 5-7 days to avoid complications to rupture and intoxication [3, 5, 6]. In our study, the number of confirmed body packers increased from three cases in the first year to 26 cases in the second. The observational period was too short to determine whether this finding represents a true increase in the amount of body packers.

Non-contrast CT is considered the first choice for screening of potential body packers [9]. In a recent study, it was suggested that the use of non-contrast magnetic resonance imaging (MRI) is equally reliable in successfully screening for body packing, and non-contrast MRI could be an ideal alternative for radiation hygiene concerns [10]. If a person is passing containers at the time of detention, there is no clinical need for the initial investigation with CT or MRI unless the body packer is symptomatic or there is doubt regarding the number of packages left in the abdomen.

There has been a change in the clinical approach to the treatment of body packers. Previously, early laparotomy was recommended, even for the asymptomatic body packers to evacuate all packages from the gastrointestinal tract to prevent rupture [11]. Presently, there is a consensus to recommend conservative treatment of body packers due to a high treatment success. In six large retrospective body packer studies, more than 98% of the total body packers (n = 3.812) were treated successfully with a conservative regimen and emergency laparotomy to evacuate packages was necessary in less than 2%, and body packing had fatal outcome in only two patients [5, 6, 8, 12-14]. As a consequence, most protocols restrict hospital admission to include only symptomatic body packers.

The observed low rate of complications to body packing in the present study as well as in other recent publications may be owed to the introduction of high-quality body packing containers, with a low risk of rupture. It has been suggested that oil-based laxatives increase the risk of dissolving latex-wrapped drug containers [1]. However, in a study of 1.181 confirmed body

packers, Veyrie et al found that oil-based laxatives can be used with risk of complications equivalent to that reported from similar reviews of body packing in which laxatives not based on oil were used [6].

The data of the present study are limited by being retrospective and by the small sample size of only 57 suspected body packers. However, our findings correspond well with those of the international literature. Future studies should establish the efficacy of screening suspects in the airport for body packing using an alternative scanning system. Thus, nearly half of the detained suspects may be incorrectly suspected body packers as in the present study. In Denmark, customs authorities have now taken up a new regimen, offering the suspect a meal and something to drink (milk) while detained in the airport. If a meal is refused it adds to the suspicion that the traveler may be carrying illegal drugs. During detention in the airport, a special toilet is used by the suspect, and the stool is contained. This altered routine procedure may lead to a better selection of the persons admitted to hospital so that fewer people are detained due to a false suspicion.

In conclusion, both suspected and confirmed body packers can be managed conservatively. However, if body packers show signs of intoxication or obstruction of the alimentary tract, there is indication for emergency operation. Package retention per se is not an indication for emergency operation.

**CORRESPONDENCE:** Peter Viktor Glovinski, Gastroenheden, Hvidovre Hospital, Kettegård Allé 30, 2650 Hvidovre, Denmark.  
E-mail: peter.viktor.glovinski.01@regionh.dk

**ACCEPTED:** 4 September 2013

**CONFLICTS OF INTEREST:** Disclosure forms provided by the authors are available with the full text of this article at [www.danmej.dk](http://www.danmej.dk).

#### LITERATURE

1. Traub SJ, Hoffman RS, Nelson LS. Body packing – the internal concealment of illicit drugs. *N Engl J Med* 2003;349:2519-26.
2. Deitel M, Syed AK. Intestinal obstruction by an unusual foreign body. *Can Med Assoc J* 1973;109:211-2.
3. Silverberg D, Menes T, Kim U. Surgery for »body packers« – a 15-year experience. *World J Surg* 2006;30:541-6.
4. Gill JR, Graham SM. Ten years of »body packers« in New York City: 50 deaths. *J Forensic Sci* 2002;47:843-6.
5. Mandava N, Chang RS, Wang JH et al. Establishment of a definitive protocol for the diagnosis and management of body packers (drug mules). *Emerg Med J* 2011;28:98-101.
6. Veyrie N, Servajean S, Aissat A et al. Value of a systematic operative protocol for cocaine body packers. *World J Surg* 2008;32:1432-7.
7. June R, Aks SE, Keys N et al. Medical outcome of cocaine body packers. *J Emerg Med* 2000;18:221-4.
8. Dorn T, Ceelen M, de Keijzer KJ et al. Prevalence and medical risks of body packing in the Amsterdam area. *J Forensic Leg Med* 2013;20:86-90.
9. Flach PM, Ross SG, Ampanozi G et al. »Drug mules« as a radiological challenge: sensitivity and specificity in identifying internal cocaine in body packers, body pushers and body stuffers by computed tomography, plain radiography and Lodox. *Eur J Radiol* 2012;81:2518-26.
10. Bulakci M, Ozbakir B, Kiris A. Detection of body packing by magnetic resonance imaging: a new diagnostic tool? *Abdom Imaging* 2013;38:436-41.
11. Suarez CA, Arango A, Lester JL, III. Cocaine-codomo ingestion. Surgical treatment. *JAMA* 1977;238:1391-2.
12. Beckley I, Ansari NA, Khwaja HA et al. Clinical management of cocaine body packers: the Hillingdon experience. *Can J Surg* 2009;52:417-21.
13. Bulstrode N, Banks F, Shrotria S. The outcome of drug smuggling by »body packers« – the British experience. *Ann R Coll Surg Engl* 2002;84:35-8.
14. Pidoto RR, Agliata AM, Bertolini R et al. A new method of packaging cocaine for international traffic and implications for the management of cocaine body packers. *J Emerg Med* 2002;23:149-53.